

LIPO-STEM

ADIPOSE TISSUE MSCs PURIFICATION KIT

**HIP OSTEOARTHRITIS CONSERVATIVE TREATMENT WITH
ADIPOSE-DERIVED MESENCHYMAL STEM CELLS:
A CASE REPORT.**

Dott. Mario Cecchetti, Dott.ssa Mara Buoro, Dott. Pietro Cecconi

Introduction

Adipose-derived mesenchymal stem cells (ADMSC), have been thoroughly studied in vitro and in vivo in the last decade, and successfully proven to be a valid therapeutic tool for the conservative treatment of a wide range of diseases (wound healing, vascular diseases, ischemic brain injuries, neurological diseases, osteoarthritis)⁽¹⁻³⁾, thanks to their reparative, anti-inflammatory and angiogenic properties.

Their use is particularly promising in the conservative treatment of early osteoarthritis: the microenvironment of the inflamed joints dictates ADMSC differentiation and their secretion of immunosuppressive and anti-inflammatory cytokines and growth factors⁽⁴⁻⁵⁾. This has a great clinical relevance, since osteoarthritis is one of the main causes of disability in the elderly population: being able to reduce symptoms and to slow the progression of this disease can have important social and economic positive drawbacks.

We present the case of hip osteoarthritis treated with autologous ADMSC, isolated with a new device: **Lipo-Stem™ (Biopsybell s.r.l., Mirandola (MO), Italy)**.

Material and methods

Since the moderate severity of osteoarthritis, arthroplasty was considered a premature solution, we opted for a conservative treatment with intra-articular injection of autologous ADMSC, processed with a new device: **Lipo-Stem™ (Biopsybell s.r.l., Mirandola (MO), Italy)**.

This is a single-use kit intended for aspiration, processing and grafting autologous adipose tissue, packed in a sterilized box containing all the components needed for the procedure. The kit (*fig. 1*) includes different sizes of syringes for adipose tissue Klein solution infiltration, adipose tissue liposuction and for fat injection, metal blunt cannulas for adipose tissue Klein solution infiltration (16 G Ø) and lipoaspiration (13 G Ø), a 16 G grafting needle, a filter bag for adipose tissue microfragmenting and washing, a drip chamber with tip to perforate the bag of saline solution with clamp, a waste collection bag.

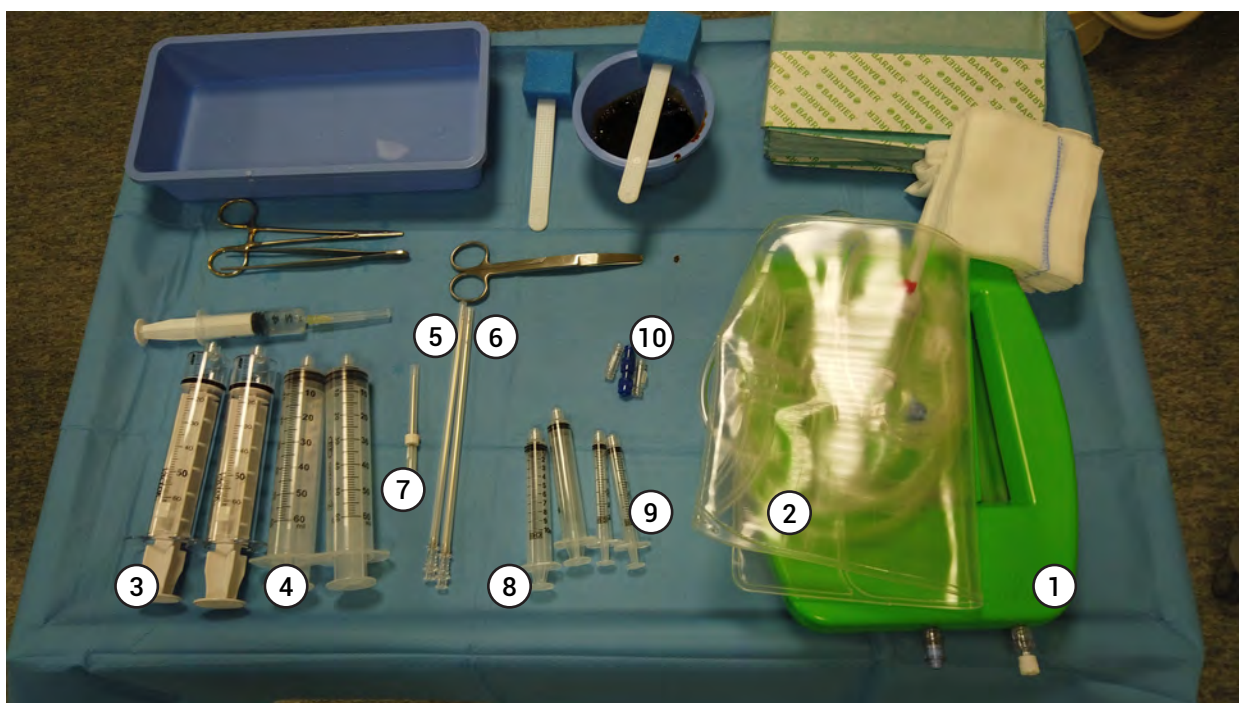


Figure 1. Surgery kit: Lipo-Stem™ kit, local anaesthetic syringe, Klein solution bowl, anchillary surgical instruments.

STANDARD KIT COMPOSITION:

- | | |
|---|--|
| 1. Lipo-Stem™ system with filtering bag | 6. Lipo-aspiration cannula 13G |
| 2. Waste bag and Infusion with clamp | 7. Infiltration needle 16G x 50mm |
| 3. VacLok syringes 60ml | 8. Syringes 10ml |
| 4. Syringes 60ml | 9. Syringes 3ml |
| 5. Klein cannula 16G | 10. Combi caps LLF/LLM and Luer connectors LLF/LLF |

Case report

In the operating room, the patient was placed in supine position and antibiotic prophylaxis was intravenously administered (Ceftriaxone 1g). The abdomen was chosen as donor site for the adipose tissue: under local anaesthesia (1 cc of a 2% Lidocaine), the subcutaneous abdominal tissue was infiltrated with 200 ml of Klein solution (*fig. 2*):

- 20 ml of 2% lidocaine
- 0.25 cc of 1 mg/ml adrenaline
- 2 cc of sodium bicarbonate
- 250 ml of 0.9% saline solution

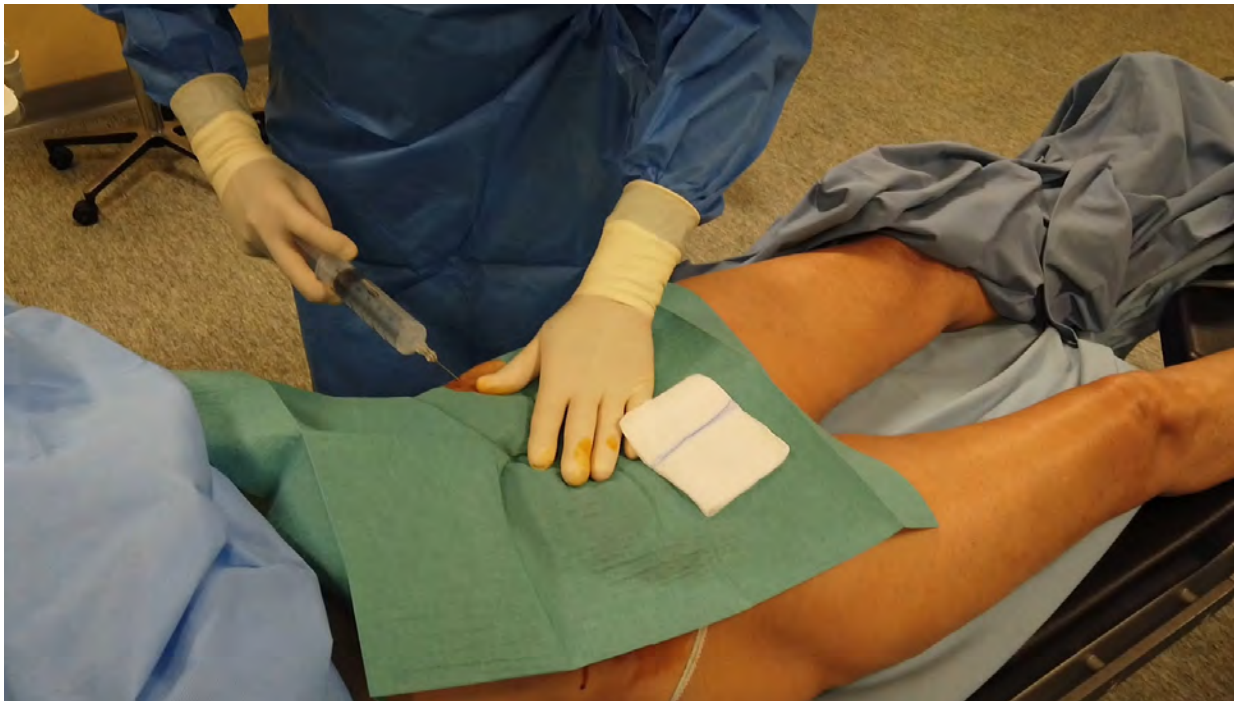

Figure 2. Klein solution infiltration in the subcutaneous abdominal tissue.

Case report

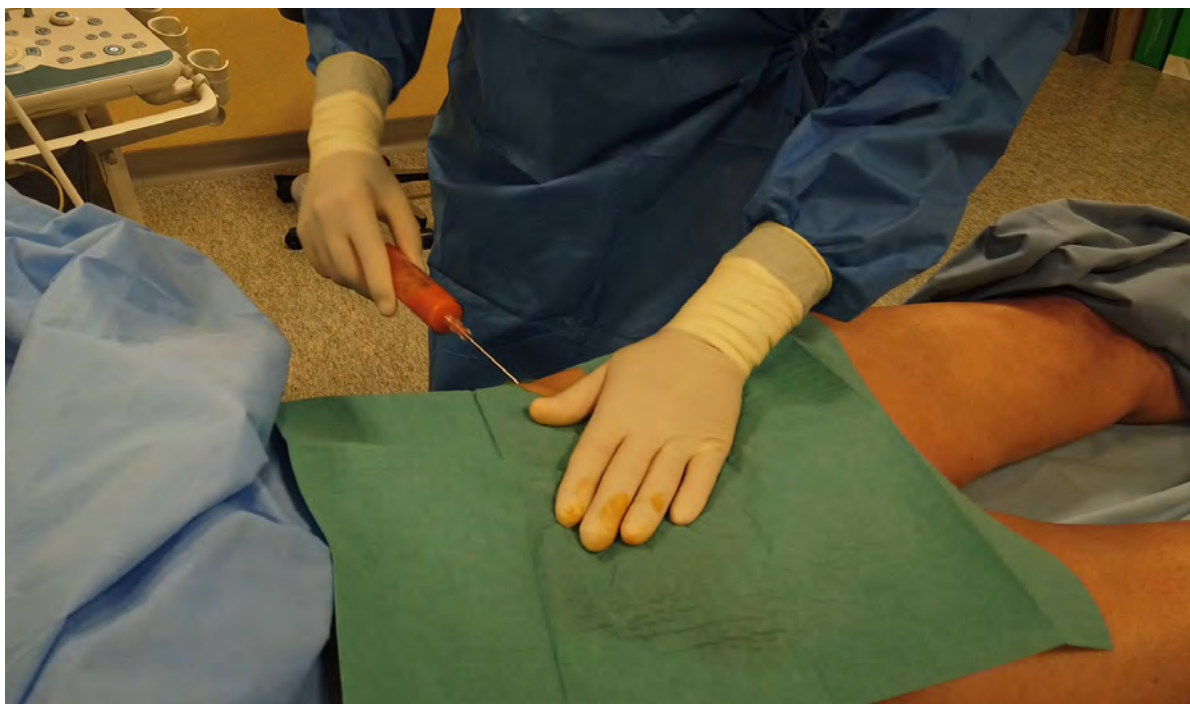

Figure 3. Lipoaspiration in the previously infiltrated area.

After 7-10 minutes, about 60 cc of adipose tissue were harvested through a wet liposuction technique (fig. 3). The abdominal incision was closed with a thin bandage, and an adhesive foam pad was applied on the treated area.

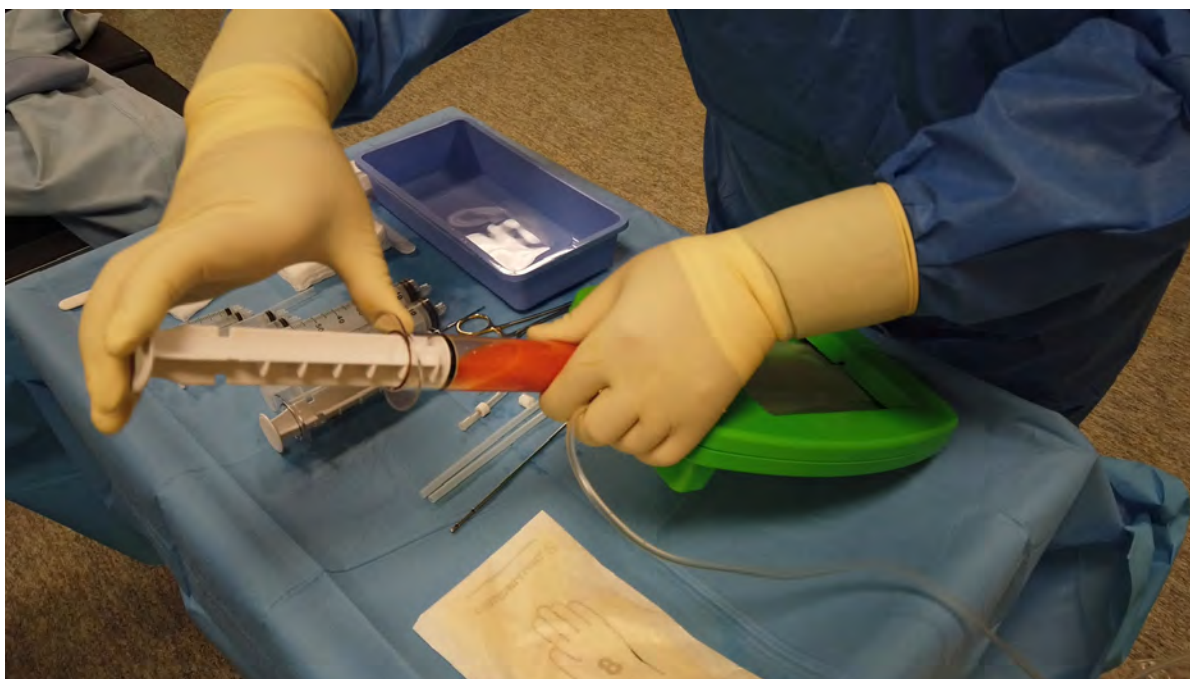

Figure 4. Lipoaspiration syringe connection to the device's LIPO-IN valve and transfer into the Lipo-Stem™ processing bag.

In the same time, the collected tissue was immediately processed with the Lipo-Stem™ device. The liposuction syringe was connected to the filter bag and the adipose tissue was transferred to the filter bag (fig. 4).

Case report

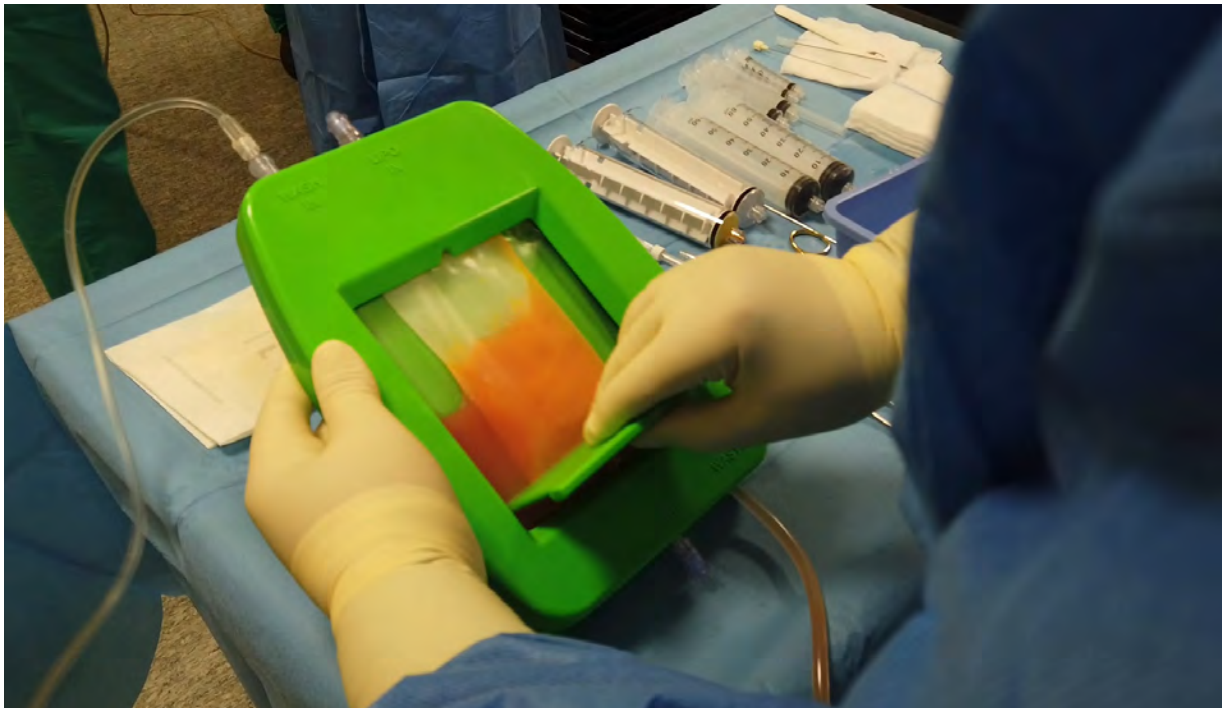

Figure 5. Adipose tissue processing phase: microfragmentation and purification (A) from all pro-inflammatory residues.

Following the manufacturer's instruction, the tissue underwent a delicate and fast mechanical processing in a continuous saline solution washing (fig. 5): the clusters of adipose tissue were reduced in size, while the blood components with pro-inflammatory properties and the oily substances were washed away and eliminated through the waste collection bag connected to the bottom of the filter box (fig. 6).



Figure 6. Waste collection bag with all pro-inflammatory residues and waste liquids (blood, oil, saline and Klein solution).

Case report



Figure 7. Adipose tissue processing phase: the resulting product.

In about 5 minutes, 9 cc of microfragmented micronized adipose tissue product were obtained (*fig. 7 and 8*) and injected intra-articularly in the right hip, after cutaneous infiltration with 1 cc of 2% lidocaine, under ultrasound guidance (*fig. 9-12*). The injection point was medicated with a sterile compressive dressing.

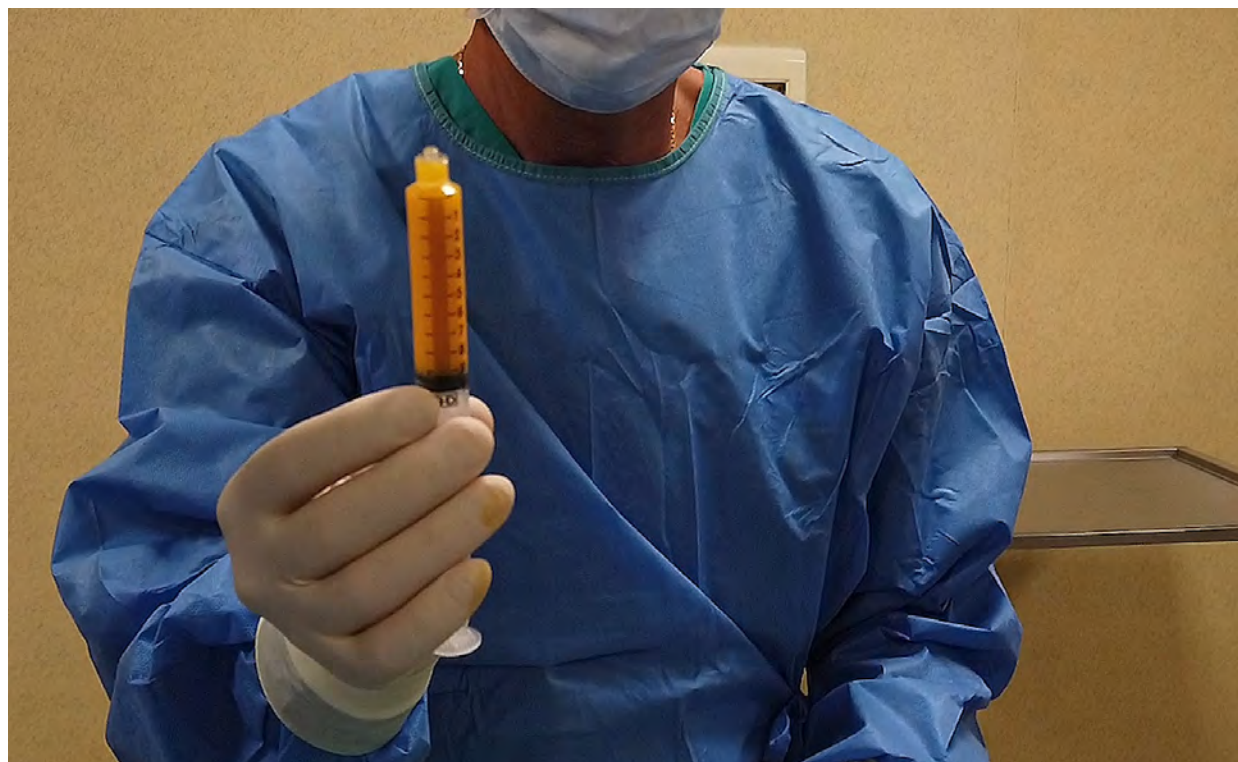

Figure 8. Microfragmented micronized adipose tissue obtained.

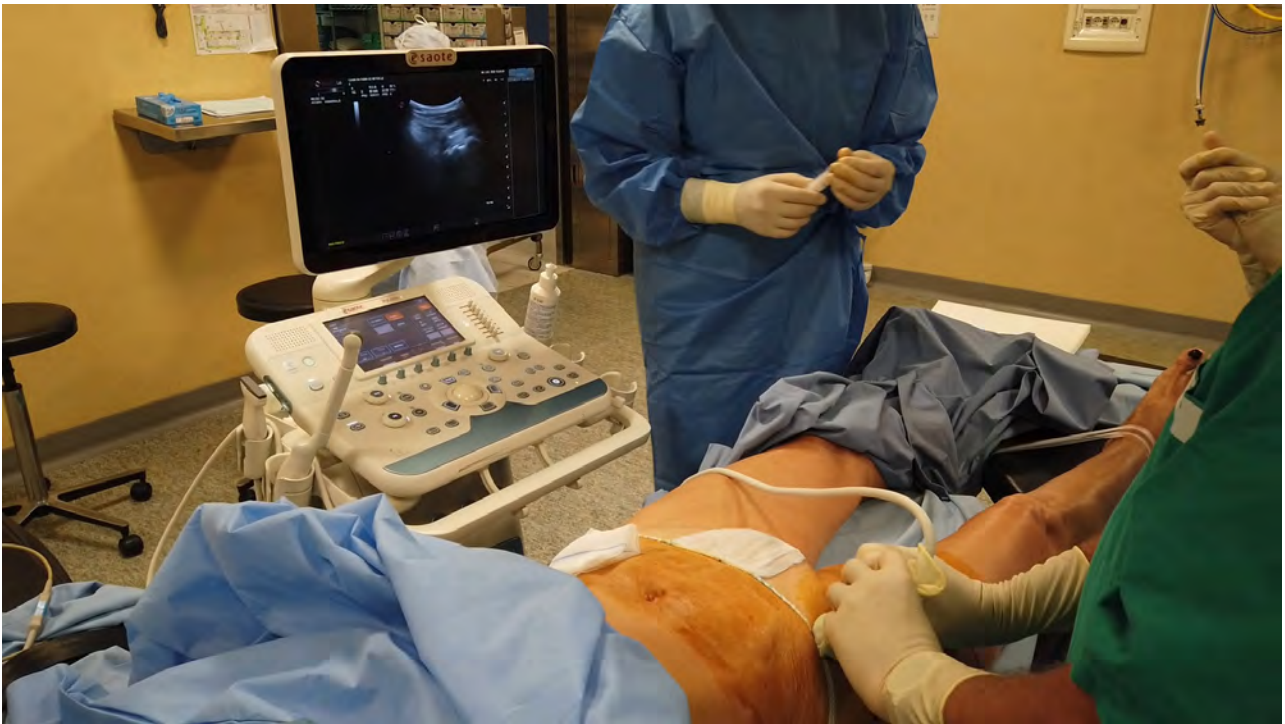

Figure 9. Target area identification under ultrasound guidance.

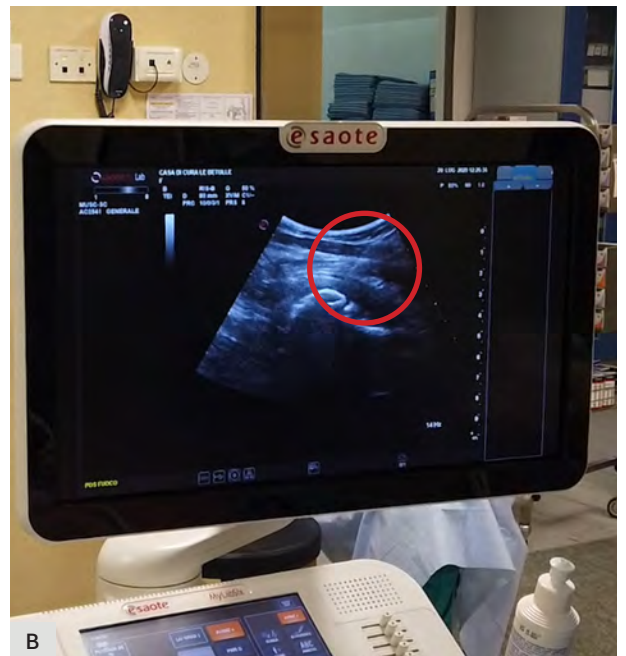
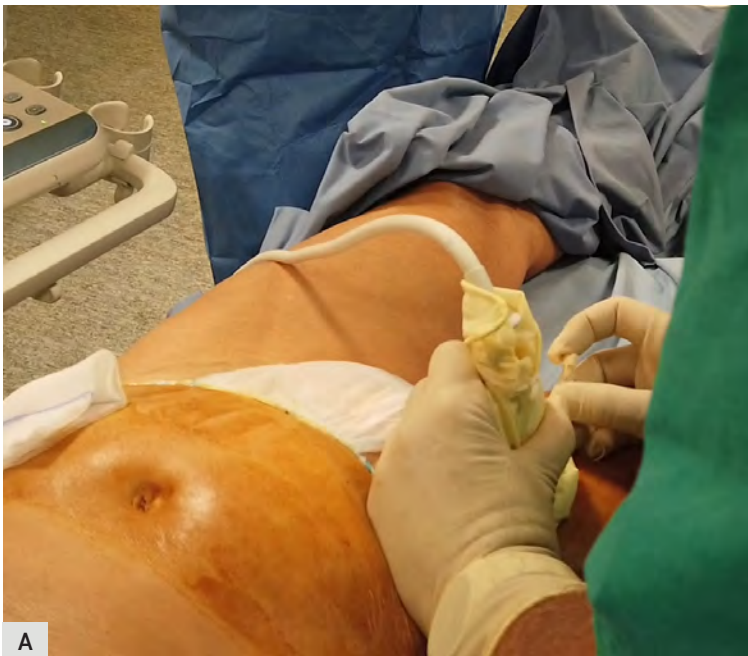
Figure 10. Needle positioning (A) under ultrasound guidance (B).

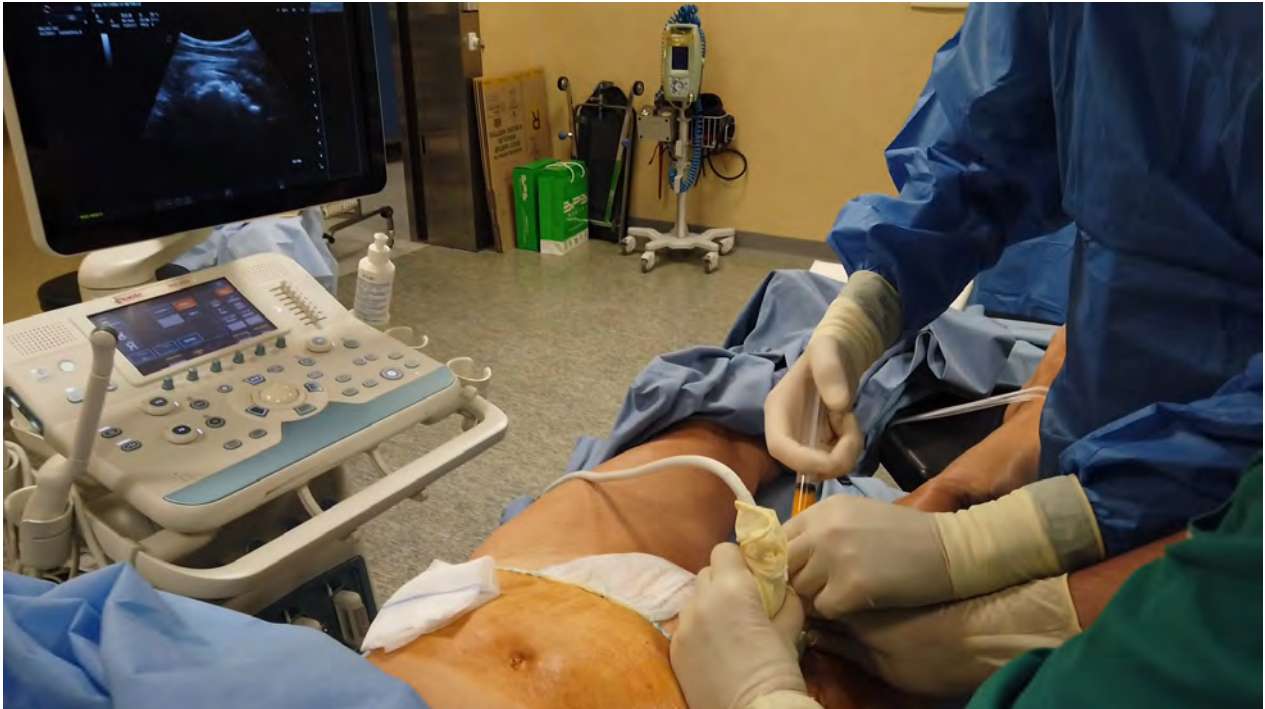

Figure 11. Micronized adipose tissue intra-articular injection in the right hip under ultrasound guidance.

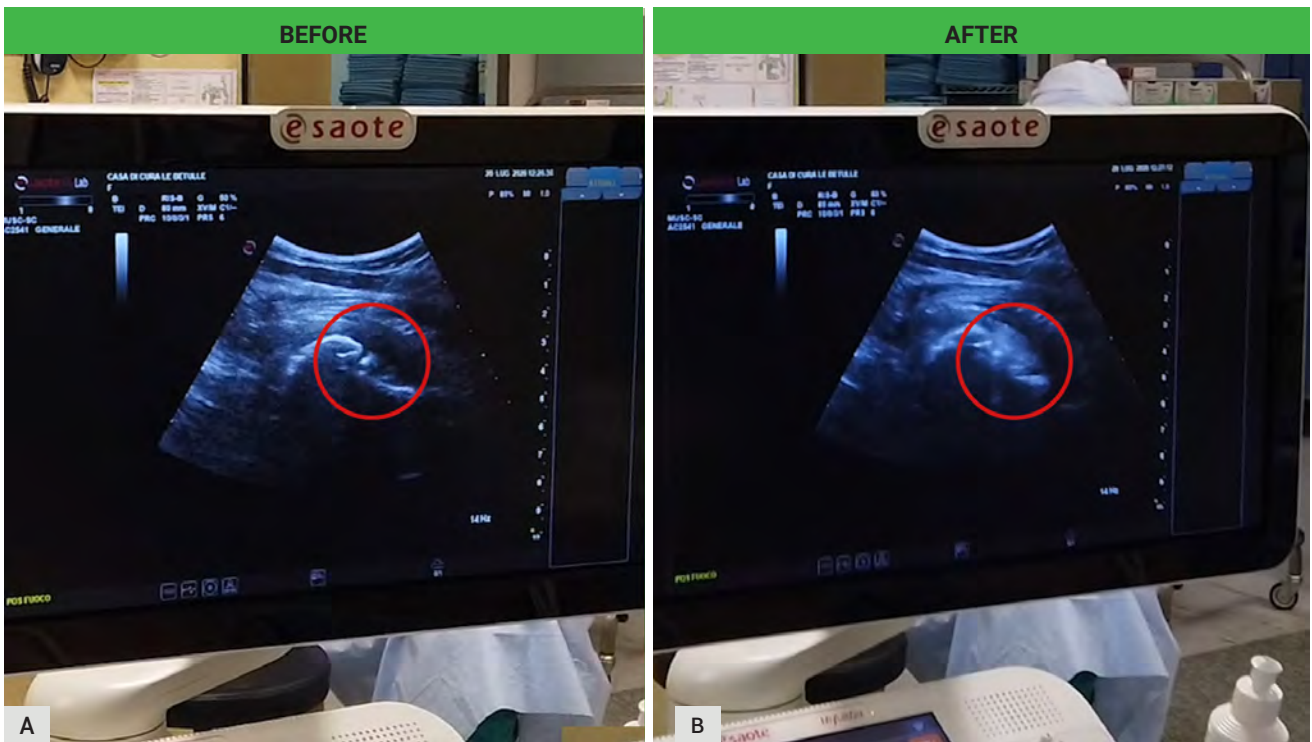


Figure 12. Final result ultrasound image comparison: BEFORE (A) and AFTER (B) treatment.

Results

The procedure was uneventful, just a moderate discomfort was perceived by the patient during the intra-articular injection. The patient was discharged 30 minutes after the procedure with paracetamol 1000 mg if needed, and with the indication to avoid efforts, but with permission to weightbearing. She referred a moderate worsening of the hip pain in the next 4-5 days, followed by a progressive improvement of symptoms and mobility in the second week postoperatively.

Outpatient controls were made at 1 and 3 months postoperatively. In this timeframe, physical examination was unremarkable, passive movement of the hip was almost painless, the range of motion was greatly improved and the patient referred an almost complete resolution of the algic symptoms, with no need for any further pharmacological or physical therapy.

Discussion

Osteoarthritis, a degenerative disease of synovial joints that causes progressive loss of articular cartilage, is the most common cause of disability in the Western world in older adults. The hip is the second most commonly affected joint, after the knee⁽⁶⁾. When resistant to conservative treatments (NSAIDs, physical therapy), hip osteoarthritis can be treated with hyaluronic intra-articular injections, which however have proven just to slow down the progression of disease. Total joint replacement is the last resort, but it can be premature in mild to moderate osteoarthritis, so in the last decade research has found in mesenchymal stem cells articular injections a promising conservative treatment option, which can not only slow down the progression of cartilage degeneration, but also give important lubricating, anti-inflammatory and regenerative support.

Perivascular cells, or pericytes, have been reported as the progenitors of mesenchymal cells⁽⁷⁾; both cellular types can be found in the extracellular matrix of various tissues, such as the bone marrow and, more abundantly, in the adipose tissue. This is an ideal donor site because of its easier access, a minimal donor site morbidity, and its richness of vascular niches, thus representing an important source of potential healing and regenerative pericytes and ADMSC⁽⁸⁾. These are multipotent cells with the ability to differentiate into various tissues (bone, tendon, articular cartilage), and having trophic, anti-scarring, immunomodulatory, mitogenic, anti-apoptotic and anti-microbial properties, due to their production of growth factors, bioactive elements and cytokines that detect and signal changes in the microenvironment where they reside⁽⁹⁾. These paracrine properties are well preserved, when lipoaspirate is delicately processed by mechanical, non-enzymatic methods⁽¹⁰⁾. A recent systematic review has shown better clinical and imaging scores in patients treated with ADMSC, with clinical improvement maintained up to 1 year and evidence of regenerated hyaline cartilage⁽⁸⁾.

Lipo-Stem™ is a new device that allows to obtain, from lipoaspirate, a micronized, microfragmented adipose product, rich in pericytes and ADMSC. Cellular structure and paracrine activity are well preserved, thanks to a delicate, simple and rapid mechanical processing of fat, that is reduced in size through a system of filters in a continuous saline solution washing system, which eliminates blood residues with pro-inflammatory properties. The final product is ready to be injected immediately, in the same operating stage, with no need for laboratory manipulation (enzymatic processing, haemolysis, culturing), thus greatly reducing the preparation time and avoiding higher costs, ethical issues and regulatory constraints.

In the reported case, both liposuction and intra-articular injection were performed under local anesthesia in less than 1 hour, the patient reported just a little discomfort during the injection. Despite a minimal worsening of the algic symptoms in the first 5 days postoperatively, she had a following progressive pain relief and a great improvement in articular mobility. No adverse events were observed, and the patient was very satisfied of the significant and prolonged improvement in pain control, functional status and quality of life, with no need for pharmacological therapy up to 3 months post-treatment.

Conclusions

Although literature lacks well designed and comparative standardized studies, autologous micronized fat injections represent a promising treatment option in osteoarthritis. Such a safe and conservative treatment represents not only an important clinical tool to reduce pain and improve the patients' quality of life, but also a reduction of social costs, limiting or delaying the need for arthroplasties. Albeit this is a single case report, part of a larger ongoing study, the results are very encouraging and **Lipo-Stem™** appears to be a very handful, safe and effective device for the conservative treatment of mild to moderate osteoarthritis or in patients not responsive to other current treatments.

REFERENCES

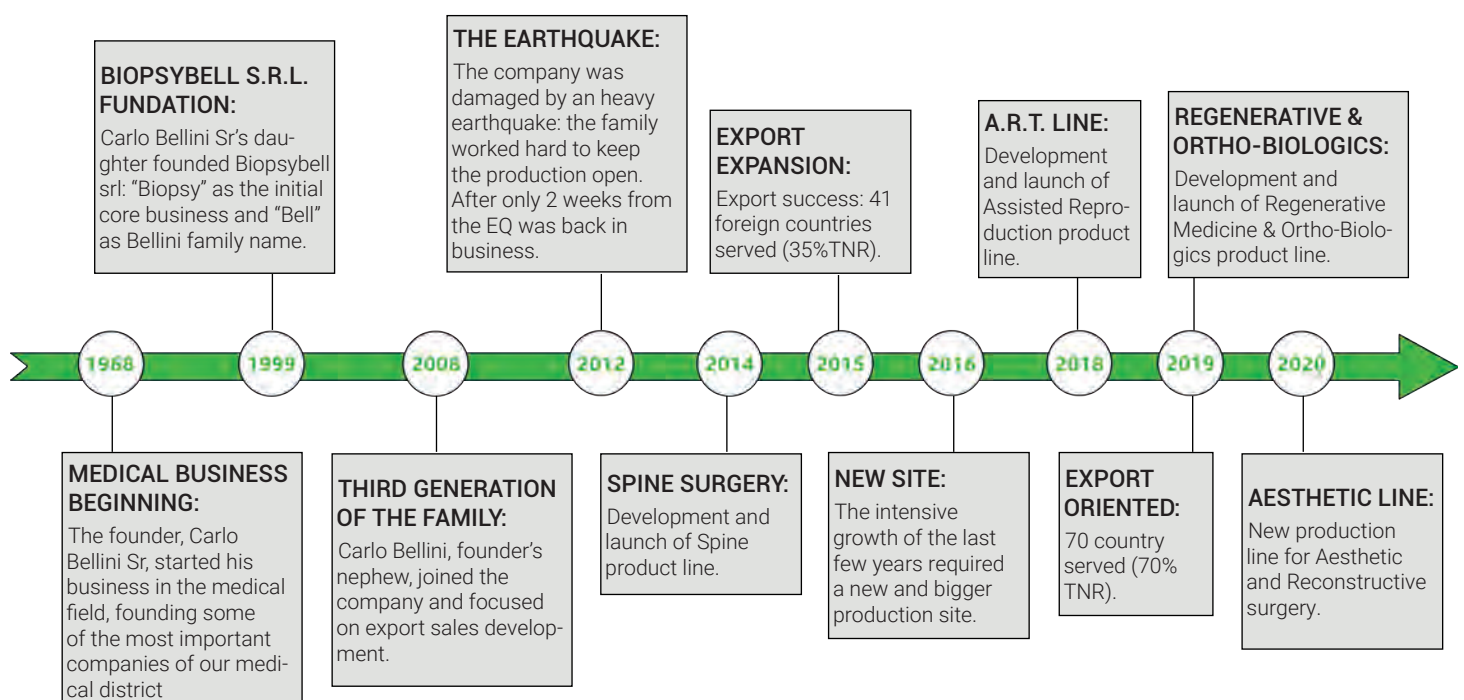
1. Bateman M.E., Strong A.L., Gimble J.M., Bunnell B.A.. "Concise review: using fat to fight disease: a systematic review of non-homologous adipose-derived stromal/stem cell therapies", *Stem Cells*, 36(9), 1311-1328, 2018.
2. Stonesifer C., Corey S., Ghanekar S., et al. "Stem cell therapy for abrogating stroke-induced neuroinflammation and relevant secondary cell death mechanisms", *Prog Neurobiol*, 158, 94-131, 2017.
3. Filho D.M., Ribeiro P.d.C., Oliveira L.F., et al. "Therapy with mesenchymal stem cells in Parkinson disease: history and perspectives", *Neurologist* 23(4), 141-147, 2018.
4. Kong L., Zheng L.Z., Quin L., Ho K.K.W.. "Role of mesenchymal stem cells in osteoarthritis treatment", *J Orthop Translat*, 9, 76-88, 2017.
5. Shi Y., Wang Y., Li Q., et al. "Immunoregulatory mechanisms of mesenchymal stem and stromal cells in inflammatory diseases", *Nat Rev Nephrol*, 14(8), 493-507, 2018.
6. Dall'Oca C., Breda S., Elena N., et al. "Mesenchymal stem cells injection in hip osteoarthritis: preliminary results", *Acta Biomed* 90(1), 75-80, 2019.
7. Crisan M., Yap S., Casteilla L., Chen C-W., et al. "A perivascular origin for mesenchymal stem cells in multiple human organs", *Cell Stem cell* 2008; 3: 301-313.
8. Usulli F.G., D'Ambrosi R., Maccario C., et al. "Adipose-derived stem cells in orthopaedic pathologies", *Br Med Bull*. 124(1):31-54, 2017.
9. Caplan A.I., Correa D. "The MSC: an injury drugstore", *Cell Stem Cell* 9: 11-15, 2011.
10. Garcia-Contreras M., Messaggio F., Jimenez O., et al. "Differences in exosome content of human adipose tissue processed by non-enzymatic and enzymatic methods", *CellR4* 3(1), 1-6, 2014.

OUR COMPANY



BPB MEDICA™ is an Italian manufacturing company specialized in the design, production and marketing of high qualitative healthcare products for medical use and medical-surgery devices.

BPB MEDICA™ was founded in 1999 by the Bellini family, boasting thirty year's experience in the biomedical sector. The founder, Carlo Bellini Sr., started the business in 1968 and has passed down to his heirs ethics, integrity and spirit of sacrifice. Today BPB MEDICA™ has leveraged its 50 years experience to develop new innovative product lines, growing the company on international level.



BPB MEDICA's™ philosophy is to grow alongside the needs of patients, doctors and hospital staff in general. Backed by the experience acquired by the company's specialized technical personnel and thanks to newly-adopted technologies, BPB MEDICA™ has quickly managed to make a name for itself on the domestic and international markets.

OUR PRODUCT LINES



**SPINE
SURGERY**



**ORTHO-
BIOLOGICS**



**ASSISTED
REPRODUCTION**



BIOPSY



**INTENSIVE
CARE**



AESTHETIC

BPB MEDICA™ provides painstaking service to its clientele and its primary aim is product quality. Our **internal Regulatory and Quality Departments** offer a full-service support to our customers on the following activities:

- Quality Systems
- Regulatory Affairs
- Technical documents preparation
- Clinical experimentation
- Vigilance
- Formation
- OEM and Private Label regulatory and quality support



Our **Quality Department** conducts rigorous tests, from the raw materials to the equipment and the finished product. This allowed the company to obtain CE, ISO 13485 and the establishment registration by FDA.

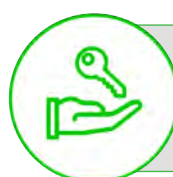

OUR SERVICES



QUALITY & REGULATORY DEP.

Our primary aim is product quality and provide painstaking service. Our regulatory and quality teams conduct rigorous tests for this purpose.



OEM & PRIVATE LABEL SERVICES

A la cart production, with customer's brand name and custom color. Full-service support of Regulatory and Quality documentations.



RESEARCH & DEVELOPMENT

Constant research in order to increase production and quality standards while developing new products.



MARKETING SUPPORT

Video tutorial, case report, presence at the major medical congresses, organization of training and courses.



PRODUCTION PROCESS CONTROL

Complete manufacturing process carried out internally, from design to final packaging.



FOUR WEEKS DELIVERY

Thanks to the optimization of the production process, we satisfy our customers orders within 4 weeks.

Thanks to the **internal R&D Department** BPB MEDICA™ conducts constant research in the reference pathologies with an aim to ever better qualifying and improving its production standards and aiding the development of new products. Functional tests are performed by **R&D Department** in concert with Quality Department to demonstrate the product performance and to make sure that new products maintain their functional characteristics even in the worst case.

BPB MEDICA™ is an established and experienced contract medical equipment manufacturer, with:

- Advanced ISO 8 clean room facility for manual & automatic assembly and packaging.
- Metal refinishing department for cutting, grinding, sharpening, cleaning, echogenic marking, sealing, reduction
- Moulding department with vertical and horizontal molding machines.
- Computerised warehouse with top selling items always available in stock ready to be shipped within 24 hours.

CUTTING, GRINDING & ELECTROPOLISHING



CLEAN ROOM



MOULDING DEPARTMENT





Contact us for further information:

BIOPSYBELL S.R.L.

Via Aldo Manuzio 24

41037 Mirandola – MO – ITALY

T. +39 0535 27850 – F. +39 0535 33526

C.F./P.Iva 02615000367



BPB MEDICA

www.biopsybell.it

international1@biopsybell.it