

## Original Article

# Chronic wound treatment with high-density nanofat grafting combined with negative pressure wound therapy

Chengliang Deng\*, Yuanzhen Yao\*, Zhiyuan Liu\*, Hai Li, Zhaowei Yang, Dali Wang, Zairong Wei

*Department of Plastic Surgery, Affiliated Hospital of Zunyi Medical College, Zunyi, Guizhou, P. R. China. \*Equal contributors and co-first authors.*

Received March 5, 2018; Accepted October 13, 2018; Epub February 15, 2019; Published February 28, 2019

**Abstract:** Negative pressure wound therapy is an essential technological advancement in wound care and stem cell therapy is the most promising treatment for chronic wounds. Nanofat grafting, an adipose-derived stem cell-based cytotherapy, has shown therapeutic potential for various conditions. However, the effects of negative pressure wound therapy combined with nanofat grafting on wound healing have not been investigated. In this study, high-density nanofat grafting combined with negative pressure wound therapy was used to treat patients with chronic wounds, while negative pressure wound therapy alone was used as the control. Data were analyzed with independent sample t-tests. A comparative study of wound healing rates, post-surgery, and histological changes revealed that average wound healing rates in the high-density nanofat combined with negative pressure wound therapy group were  $26.50\% \pm 9.51\%$ , compared to  $12.02\% \pm 4.20\%$  in the negative pressure wound therapy alone group. There were statistically significant differences ( $P < 0.01$ ). Histological analysis using hematoxylin and eosin and Masson's trichrome staining, along with CD31 immunohistochemistry, showed less lymphocyte infiltration, greater collagen accumulation, and newly formed vessel growth in the high-density nanofat combined with negative pressure wound therapy group, compared with the control group. High-density nanofat grafting combined with negative pressure wound therapy is a safe and effective option, enhancing chronic wound healing.

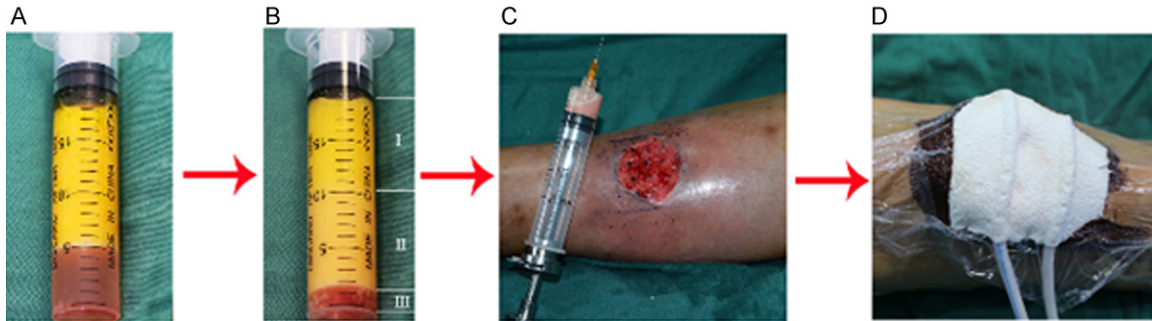
**Keywords:** Adipose-derived stem cells, nanofat, negative pressure wound therapy, stromal vascular fraction, wound healing

## Introduction

Chronic wounds are characterized as wounds that have not proceeded, within 3 months, through systematic and timely reparation to produce anatomic and functional integrity [1]. Chronic wounds are an important social and economic burden. Incidence of these wounds has continued to increase because of a sharp growth in the aging population and in cardiovascular and metabolic disease, worldwide. It has been estimated that approximately 1-2% of individuals, at any given time, are affected by chronic wounds [2, 3]. Therefore, treatment of chronic wounds is very important and challenging work. However, discovering an optimal therapy for chronic wounds has remained a major challenge for clinicians [4].

Stem cell therapy has been proposed as a treatment for chronic wounds based on the precise physiologic requirements for chronic wound healing, including reepithelization of the wound, angiogenesis, and immunomodulation [5, 6]. Therefore, stem cell therapy has been considered the most promising treatment for chronic wounds [7]. Although bone marrow-derived mesenchymal stem cells (MSCs) were the first stem cells used, clinically, to accelerate wound healing [8, 9], adipose-derived stem cells (ASCs) are superior in many ways, including their ease of harvest, abundance within adipose tissue, and advantages in proangiogenic properties and immunomodulatory effects [10, 11]. Moreover, stromal vascular fraction (SVF) of adipose tissue containing ASCs has been shown to have reparative and regenerating

## Nanofat grafting combined with NPWT for chronic wounds



**Figure 1.** Schematic diagram of treatment with high-density nanofat grafting combined with NPWT for chronic wounds. A. Coleman fat after the first centrifugations. B. Nanofat after the second centrifugations: I, low-density nanofat layer; II, high-density nanofat layer; III, aqueous layer. C. High-density nanofat grafting. D. NPWT. NPWT, negative pressure wound therapy.

effects in preclinical and clinical studies, strongly suggesting that it plays a pivotal role in chronic wound healing [12, 13]. However, the isolation of SVF or ASCs requires digestion with collagenase, increasing the risk of both the introduction of exogenous material in the preparation and biological contamination [14]. In addition, clinical application of SVF/ASCs for wound healing may be limited because of poor survival of ASCs in vascular wound beds and elimination of ASCs by the immune system [15-17]. These factors weaken the therapeutic effects and application of ASCs-based cytotherapy.

Recently, Piccolo et al. described the beneficial effects of autologous fat grafting on refractory wounds [18]. However, it has been reported that most adipocytes become necrosed after fat grafting and low concentrations of ASCs play a modest role in the beneficial effects of autologous fat grafting [19, 20]. In 2013, Tonnard et al. proposed a new fat grafting technique, known as nanofat grafting, which destroys mature adipocytes by purely physical methods, leaving only water, oil droplets, SVF, and the extracellular matrix [21]. Nanofat, as an ASCs-based cytotherapy, overcomes the shortcomings of SVF or ASCs suspensions, including collagenase digestion and poor survival. It has been reported that nanofat grafting can promote facial rejuvenation [21]. One study indicated that nanofat grafting combined with skin grafting can be used to manage problematic wounds [22]. An additional beneficial effect is that it can be used to treat vulvar lichen sclerosis [23]. However, concentrations of ASCs in nanofat are very low, only  $1 \times 10^3/\text{mL}$ . This is much lower than cell concentrations required for stem cell therapy.

Negative pressure wound therapy (NPWT), also known as vacuum-assisted closure, micro-deformational wound therapy, or vacuum sealing drainage, is one of the most essential technological advancements in wound care. It has been used as a “bridge” technique for wounds that cannot be immediately closed by either primary intention or plastic surgical techniques [24]. However, the effects of NPWT combined with nanofat grafting on wound healing have not been investigated. Therefore, to increase the concentration of ASCs, this study further processed nanofat through several centrifugations to harvest high-density nanofat. High-density nanofat grafting combined with NPWT was then used to treat patients with chronic wounds, while NPWT alone was used as a control. A comparative study of wound healing rates, 10 days post-surgery, and histological changes was performed. To the best of our knowledge, this is the first study concerning the clinical application of nanofat grafting combined with NPWT for treatment of chronic wounds.

### Materials and methods

#### *Ethics approval*

Patients with chronic wounds were hospitalized in the Affiliated Hospital of Zunyi Medical College. Before participation, written informed consent was obtained from all patients. This study was approved by the Ethics Committee of the Affiliated Hospital of Zunyi Medical College.

#### *Inclusion and exclusion criteria*

Inclusion criteria for the study were: (1) Age between 18 and 80 years; (2) Duration of the

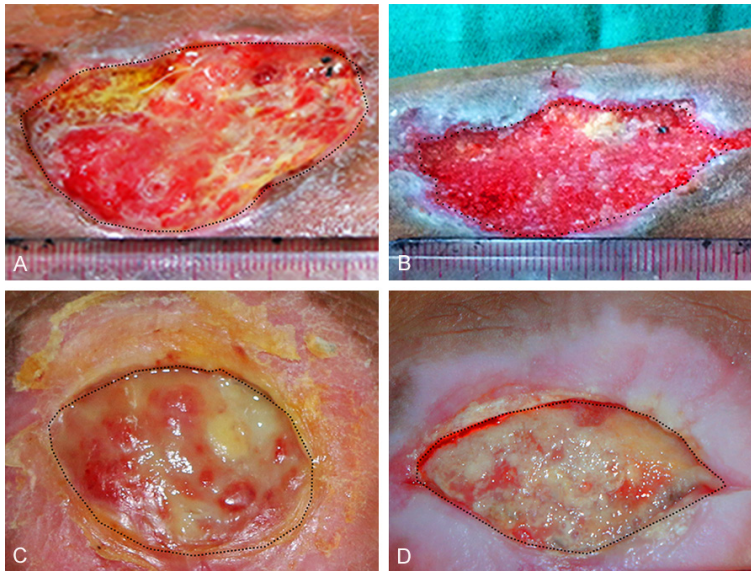
## Nanofat grafting combined with NPWT for chronic wounds

**Table 1.** Summary of patient backgrounds and wound characteristics

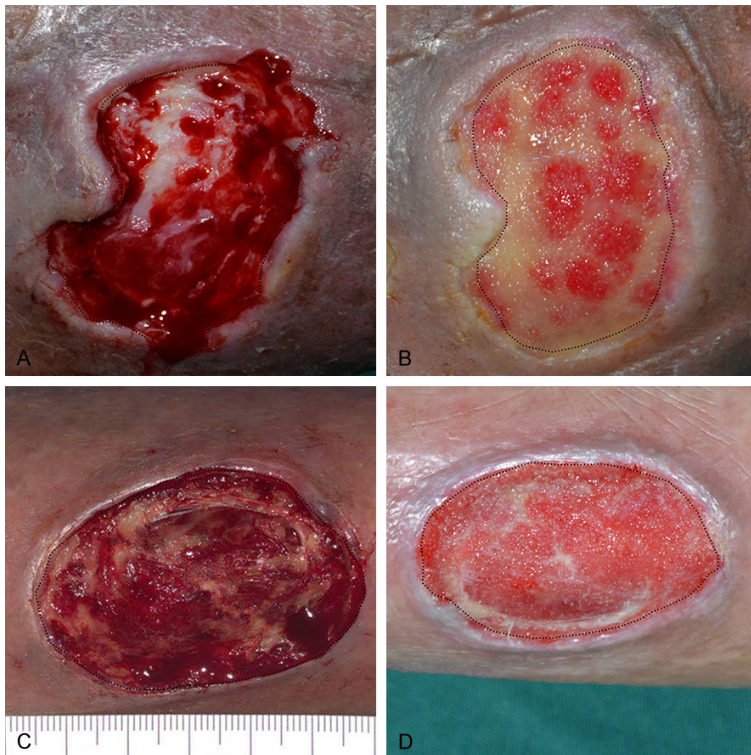
Patient number	Age/ Sex	Etiology or risk factors of chronic wound	Wound site	Duration of wound (months)	Original wound size (cm <sup>2</sup> )	Wound size after 10 days (cm <sup>2</sup> )	Wound healing rate (%)	Wound treatment
1	42/F	Traumatic infection, hypertension, and obesity	Left leg	3	8.89	4.98	43.98	Nanofat+ NPWT
2	55/M	Traumatic infection	Right knee	5	4.23	3.49	17.49	Nanofat+ NPWT
3	46/M	Venous stasis ulcer	Left leg	6	7.86	4.99	36.51	Nanofat+ NPWT
4	53/M	Venous stasis ulcer	Right leg	7	21.27	16.05	24.54	Nanofat+ NPWT
5	48/M	1. Venous stasis ulcer 2. Great saphenous varices	Left leg	5	15.78	11.79	25.29	Nanofat+ NPWT
6	51/M	Scar ulcer and traumatic infection	Left leg	8	11.05	8.19	25.88	Nanofat+ NPWT
7	65/M	Diabetic foot	Left leg	4	9.59	8.11	15.11	Nanofat+ NPWT
8	80/M	Traumatic infection	Right leg	3	13.90	10.68	23.21	Nanofat+ NPWT
9	47/F	Traumatic infection and Obesity	Right hand	3	87.81	75.3	14.25	NPWT
10	73/F	Traumatic infection	Left heel	3	11.64	11.07	4.90	NPWT
11	56/M	Venous stasis ulcer	Right leg	4	12.56	11.15	11.23	NPWT
12	53/M	Venous stasis ulcer and great saphenous varices	Left leg	3	8.98	7.52	16.26	NPWT
13	66/M	Venous stasis ulcer and great saphenous varices	Right leg	12	5.55	5.10	8.01	NPWT
14	59/F	Traumatic infection	Right leg	4	18.86	16.17	14.26	NPWT
15	56/M	Burn and skin tissue infection	Left knee	5	24.78	21.00	15.25	NPWT

F, female; M, male; NPWT, negative pressure wound therapy.

## Nanofat grafting combined with NPWT for chronic wounds



**Figure 2.** Wound changes after high-density nanofat grafting combined with NPWT. Patient 1: (A) A chronic left leg wound with an original area of 8.89 cm<sup>2</sup>. (B) Residual area 10 days post-treatment is 4.98 cm<sup>2</sup>. Patient 2: (C) A chronic right knee wound with an original area of 4.23 cm<sup>2</sup>. (D) Residual area 10 days post-treatment is 3.49 cm<sup>2</sup>. NPWT, negative pressure wound therapy.



**Figure 3.** Wound changes after high-density nanofat grafting combined with NPWT. Patient 7: (A) A diabetic foot wound with an original area of 9.59 cm<sup>2</sup>. (B) Residual area 10 days post-treatment is 8.11 cm<sup>2</sup>. Patient 8: (C) A chronic right leg wound with an original area of 13.90 cm<sup>2</sup>. (D) Residual area 10 days post-treatment is 10.68 cm<sup>2</sup>. NPWT, negative pressure wound therapy.

wound > 3 months; (3) Etiology of chronic wounds, such as diabetic wounds, infectious wounds, venous stasis ulcers, scar ulcers, vascular ulcers, or pressure ulcers; and (4) The ability to provide written informed consent. Exclusion criteria were: (1) Being in critical condition (e.g., shock from various disorders, multiple organ dysfunction syndrome, and serious infections); (2) History of any hematological disease; (3) Having a psychiatric history; (4) Being severely malnourished or significantly underweight; (5) Pregnant; and (6) Participating in another clinical trial.

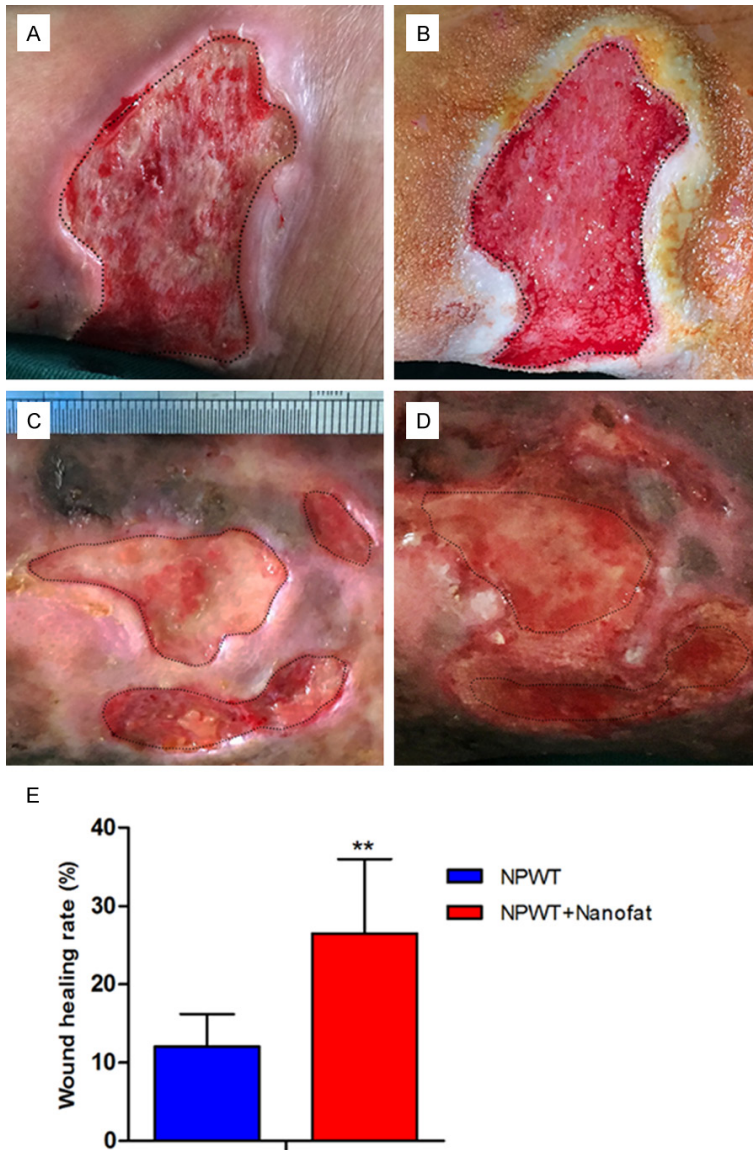
### *Harvesting high-density nanofat*

Nanofat was prepared according to previously described methods [21]. First, the liquid portion was discarded after centrifuging at 1200 g for 3 minutes. Dry fat was then mechanically emulsified by transferring it between two 10-mL syringes connected by a female-to-female Luer-Lok. After processing, the fat turned into an emulsion and it was filtered using a Nano Transfer filter (Tulip Medical Products, San Diego, CA, USA) to remove connective tissue remnants. Next, the mixture was processed by centrifugation at 2000 g for 3 minutes. This resulted in three layers in the centrifuge tube, low-density nanofat layer, high-density nanofat layer, and a small aqueous layer (**Figure 1A-D**).

### *SVF isolation and cell counting*

SVF cells were isolated from original nanofat and high-density nanofat. Briefly, the fat was digested (30 minutes in a

## Nanofat grafting combined with NPWT for chronic wounds



**Figure 4.** Wound changes after treatment with NPWT alone. Patient 10: (A) A chronic left heel wound with an original area of 11.64 cm<sup>2</sup>. (B) Residual area 10 days post-treatment is 11.07 cm<sup>2</sup>. Patient 13: (C) A chronic right hand wound with an original area of 5.55 cm<sup>2</sup>. (D) Residual area 10 days post-treatment is 5.10 cm<sup>2</sup>. (E) Quantification of the wound area of the different treatment groups. \*\*P < 0.01. NPWT, negative pressure wound therapy.

shaker, at 37°C) with phosphate buffered saline containing 0.075% collagenase. Mature adipocytes and connective tissue were removed by centrifugation at 800 g for 5 minutes. Cell pellets were then resuspended and filtered through a 100 µm mesh. Finally, the number of SVF cells was counted using an automated cell counter (Countstar, IC1000, Shuangda Biotechnologies Inc, Shanghai, China).

### *Surgical intervention of chronic wounds*

Under spinal anesthesia, liposuction of the thighs was performed and high-density nanofat was prepared, as described previously. The wound was debrided and the high-density nanofat was applied. The volume of high-density nanofat applied was based on the area of the wound, approximately 2 mL/cm<sup>2</sup>. Approximately three-fourths of the prepared high-density nanofat was injected directly into the base and edges of the wound. The remaining gel was used to cover the wound as a dressing. Finally, the treated wound was covered with negative pressure drainage. The control group was only treated with negative pressure drainage. Digital photographs of the wounds were taken 10 days postoperatively. Peri-wound tissues were harvested by punch biopsy and fixed in 10% paraformaldehyde for histological analysis.

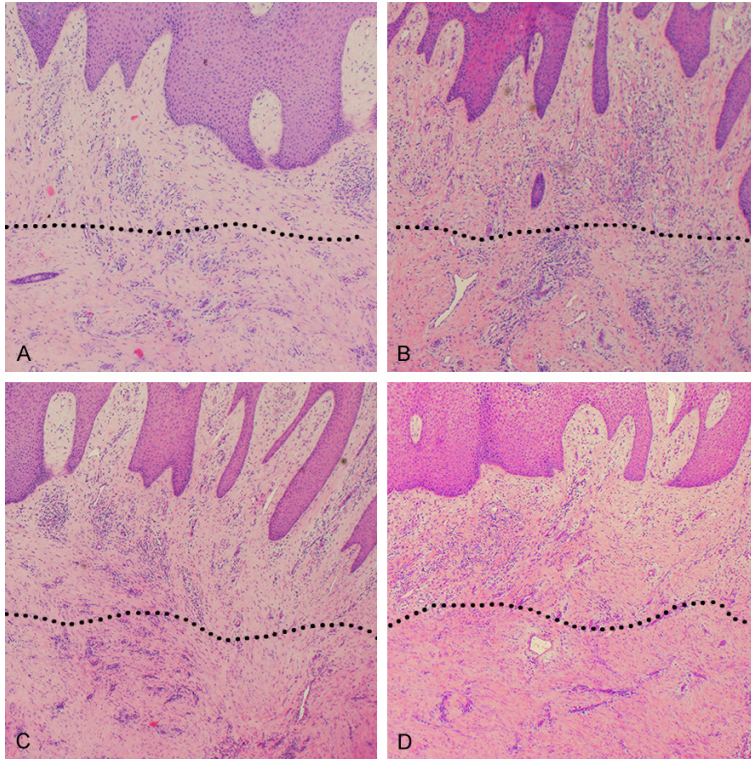
### *Wound healing rates*

On post-surgical day 10, the residual wound area was calculated by the pixel/area ratio using the Adobe Photoshop CS6.0 program (Adobe Systems, San Jose, CA, USA). Finally, wound healing rates were calculated as follows: (original wound area - residual wound area)/original wound area × 100%.

### *Histological analysis*

Peri-wound tissues were fixed in 10% paraformaldehyde, then the tissue samples were embedded in paraffin and cut into approximately 4-mm sections. To observe the tissue morphology, the sections were processed and stained with hematoxylin and eosin (H&E). To observe collagen deposition, the sections were stained

## Nanofat grafting combined with NPWT for chronic wounds



**Figure 5.** H&E staining of the wound area. A. Numerous inflammatory cells infiltrate the deep dermal layers (below the dotted line) before treatment with NPWT alone. B. Numerous inflammatory cells infiltrate the deep dermal layers (below the dotted line) before high-density nanofat grafting combined with NPWT. C. Inflammatory cell infiltration is not significantly changed (below the dotted line) after NPWT alone. D. Inflammatory cell infiltration is significantly improved (below the dotted line) after high-density nanofat grafting combined with NPWT. H&E, hematoxylin and eosin; NPWT, negative pressure wound therapy.

with Masson's trichrome. Relative collagen expression was calculated using Image J (National Institute of Mental Health, Bethesda, MD, USA). Neovascularization was evaluated after CD31 immunostaining and the number of new blood vessels per 5 high-power fields was counted.

### Statistical analysis

Results are expressed as mean  $\pm$  standard deviation. Data were analyzed with independent sample t-tests using SPSS version 19.0 (IBM, Corp., Armonk, NY, USA).  $P < 0.05$  indicates statistical significance.

### Results

#### *Cellular components of high-density nanofat*

SVF cell numbers in each sample suggested that SVF cell density increased sharply after

mechanical processing ( $8.2 \times 10^4 \pm 1.4 \times 10^4$  cells/mL in original nanofat and  $2.2 \times 10^5 \pm 0.3 \times 10^5$  cells/mL in high-density nanofat).

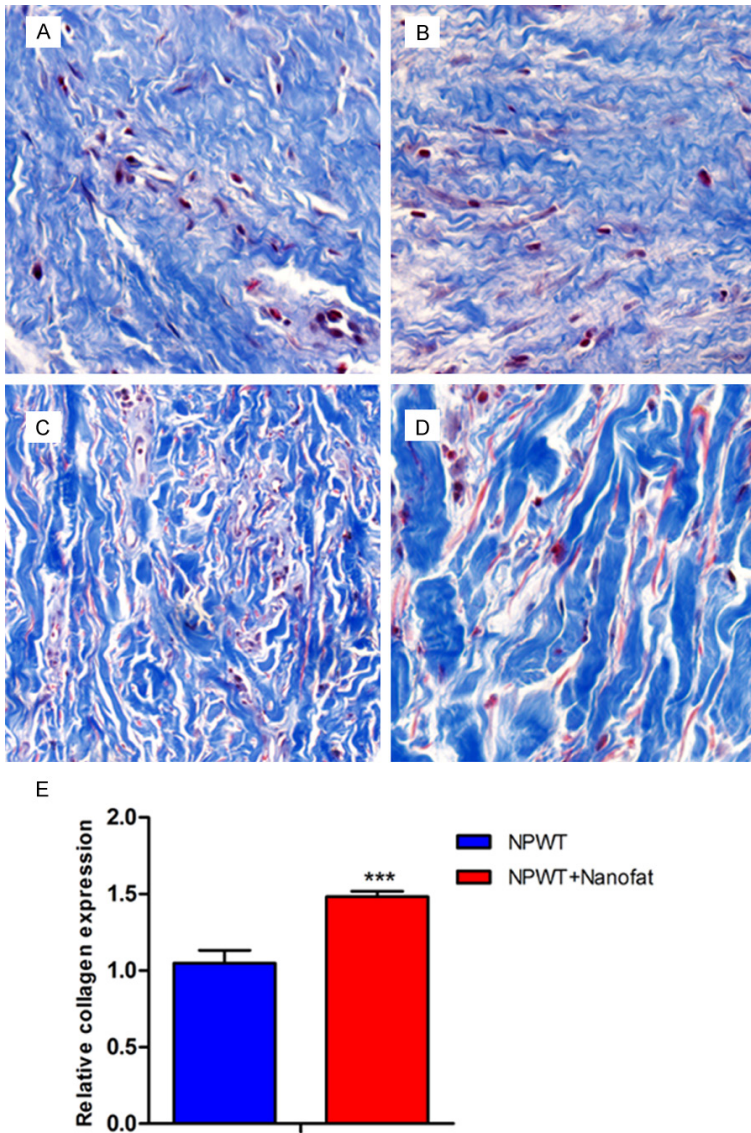
#### *Wound healing rates*

Fifteen patients admitted to the Affiliated Hospital of Zunyi Medical College, between January 2016 and October 2017, were enrolled and evaluated (11 men and 4 women, aged 42-80 years). Wound types included 6 venous stasis ulcers, 6 traumatic infections, 1 scar ulcer, 1 diabetic foot, and 1 burn wound (Table 1). Although these complex chronic wounds were treated with different interventions after transplantation of autologous high-density nanofat, all patients achieved good outcomes. Average wound healing rate for the 8 patients that received high-density nanofat combined with NPWT was  $26.50\% \pm 9.51\%$ . The rate was  $12.02\% \pm 4.20\%$  for the 7 patients receiving NPWT alone. Differences were statistically significant ( $P < 0.01$ ) (Figures

2A-D, 3A-D, 4A-E). Although nanofat was harvested from the thighs, ipsilaterally or bilaterally, there were no donor site complications.

#### *Histological analysis*

H&E staining of paraffin specimens from the peri-wound tissue revealed that lymphocyte infiltration of the deep dermal layers was decreased, indicating a reduction in the lymphocyte-mediated chronic inflammatory response following high-density nanofat administration 10 days after treatment (Figure 5A-D). Tissues stained with Masson's trichrome stain were examined for collagen deposition, revealing greater collagen accumulation in the high-density nanofat combined with NPWT group than in the NPWT alone group ( $P < 0.001$ ). Collagen was obviously thicker in the nanofat combined with NPWT group than in the NPWT alone group (Figure 6A-E). Immunohistoche-



**Figure 6.** Masson's trichrome stain of the wound area. A. Thin collagen layer before NPWT alone. B. Thin collagen layer before high-density nanofat grafting combined with NPWT. C. The collagen layer is thicker after NPWT alone. D. The thickest collagen layer is seen after high-density nanofat grafting combined with NPWT. E. Relative quantification of collagen density. \*\*\* $P < 0.001$ . NPWT, negative pressure wound therapy.

mistry with CD31 indicated more newly formed vessels in the nanofat combined with NPWT group than in the NPWT alone group ( $P < 0.001$ ) (Figure 7A-E).

### Discussion

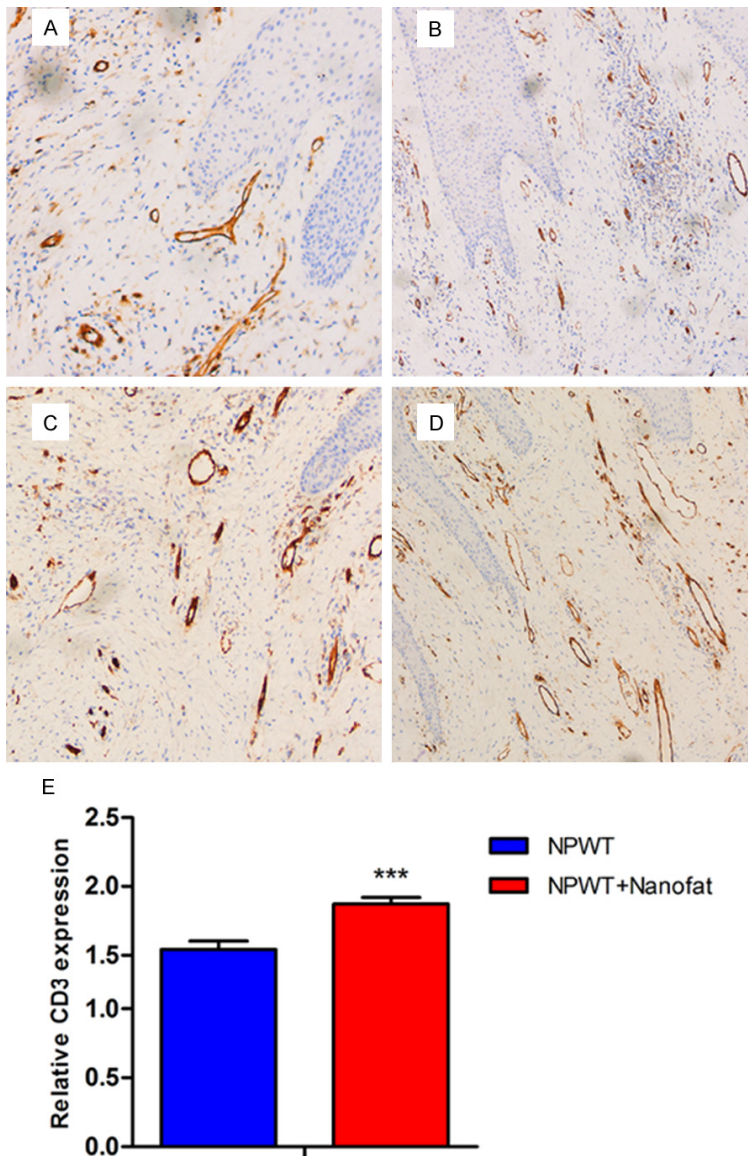
Although moderate beneficial effects of nanofat grafting or NPWT for acceleration of wound healing have been reported [22, 25], the effects of nanofat grafting combined with NPWT on wound healing have not been investigated. The

present study found that high-density nanofat grafting combined with NPWT can markedly enhance wound healing rates, compared to NPWT alone. In addition, histological analysis indicated that nanofat grafting combined with NPWT accelerates wound healing by reducing the infiltration of inflammatory cells, increasing collagen deposition, and promoting neovascularization. Collectively, present results suggest that there are synergistic effects between nanofat and NPWT that promote accelerated wound healing.

Currently, NPWT is one of the most widespread techniques used to treat chronic wounds [25]. Possible mechanisms of NPWT in wound care include the stimulation of granulation tissue formation, decrease in matrix metalloproteinases, stimulation of angiogenesis, and less edema formation, leading to improved blood flow and reduced bacterial colonization [25-27]. However, chronic wounds require multiple treatments because of the dynamic and irregular wound environment [9]. Hence, it is improbable that one type of treatment alone will result in complete wound healing [9]. A recent large randomized trial suggested that the most important function of NPWT is to promote granulation tissue and gener-

ate a "curative" environment inside a wound rather than specifically to achieve wound closure [28]. Similarly, present results demonstrated that the wound healing rate at 10 days after treatment was only  $12.02\% \pm 4.20\%$  in the NPWT alone group. However, this treatment resulted in better granulation tissue formation. Similarly, Langer et al. [25] reported that there were statistically significant differences in the volume of the wounds before and after the application of NPWT. Average reduction in wound size per week was 17.44% in chronic

## Nanofat grafting combined with NPWT for chronic wounds



**Figure 7.** Immunohistochemistry analysis of the wound area with CD31. A. Rare neovascularization before NPWT alone. B. Rare neovascularization before high-density nanofat grafting combined with NPWT. C. Neovascularization is increased after NPWT alone. D. The most neovascularization is seen after high-density nanofat grafting combined with NPWT. E. Relative quantification of neovascularization. \*\*\* $P < 0.001$ . NPWT, negative pressure wound therapy.

lower limb wounds in their 34 patients. Minor differences in wound healing rates may be related to the duration of chronic wounds, severity of the condition, and negative pressure suction. However, in contrast, the average wound healing rate of high-density nanofat combined with NPWT group was  $26.50\% \pm 9.51\%$ , considerably higher than that of the NPWT alone group. Differences in wound heal-

ing rates may be due to the transplantation of high-density nanofat.

Traditional nanofat includes water, oil droplets, SVF, and extracellular matrix. Concentrations of ASCs within nanofat are very low, only  $1 \times 10^3/\text{mL}$ . This is much lower than cell concentrations required for stem cell therapy. Therefore, traditional nanofat is further processed and purified through a purely physical method, resulting in high-density nanofat whose volume is approximately 30% of the initial nanofat volume. As a result, concentrations of ASCs within the high-density nanofat are effectively improved, increasing the clinical benefits. Present data showed that the number of SVF cells in original nanofat was  $8.2 \times 10^4 \pm 1.4 \times 10^4$  cells/mL while that in high-density nanofat was  $2.2 \times 10^5 \pm 0.3 \times 10^5$  cells/mL. It has been established that ASCs have the potential to promote angiogenesis and secrete a significant amount of growth factors, showing immunomodulatory effects [29]. In the present study, H&E staining revealed that the lymphocyte infiltration in the dermal layers was obviously decreased after injections of high-density nanofat. Results confirm the immunomodulatory effects of ASCs on lymphocyte-mediated chronic inflammatory response. Additionally, collagen syn-

thesis and neovascularization is essential for wound healing [30]. Histological analysis demonstrated that collagen accumulation and newly formed vessels were higher in the high-density nanofat combined with NPWT group than in the NPWT alone group. Results suggest that there could be synergistic effects between high-density nanofat and NPWT that promote accelerated wound healing. Similarly, Sahin et



al. [31] reported that NPWT combined with MSCs improved the neovascularization of an acellular dermal matrix (ADM) application to Sprague-Dawley rats with wounds. Results revealed that the application of NPWT with MSCs to wounds significantly accelerated the neovascularization of ADM, more than NPWT or MSCs alone, suggesting that the combination of NPWT with MSCs has synergistic effects on angiogenesis.

There were limitations to this study, however. The information presented in this study was limited by its small sample size, although the patients obtained satisfactory outcomes. In addition, because of ethical issues, single injections of high-density nanofat were not included in the control group. Moreover, optimal volumes, transplant timing, and number of transplants of high-density nanofat requires further study. Once a standard protocol has been identified, a large multicenter clinical controlled trial should be performed. However, the present study indicates that high-density nanofat transplantation is a valuable treatment for chronic wounds.

### Conclusion

High-density nanofat grafting combined with NPWT can accelerate wound healing by reducing the infiltration of inflammatory cells, increasing collagen deposition, and promoting neovascularization. There may be synergistic effects between nanofat and NPWT on wound healing. This combination can be an effective and safe option for treatment of chronic wounds.

### Acknowledgements

This work was supported by the National Nature Science Foundation of China (81660323).

### Disclosure of conflict of interest

None.

**Address correspondence to:** Drs. Dali Wang and Zairong Wei, Department of Plastic Surgery, Affiliated Hospital of Zunyi Medical College, 149 Dalian Road, Zunyi 563000, Guizhou, P. R. China. Tel: +86-18089643777; Fax: +86-085128622043; E-mail: daliwangzy@sina.com (DLW); Tel: +86-15208520-008; Fax: +86-085128622043; E-mail: zairongwei@163.com (ZRW)

### References

- [1] Werdin F, Tenenhaus M and Rennekampff HO. Chronic wound care. *Lancet* 2008; 372: 1860-2.
- [2] Crovetti G, Martinelli G, Issi M, Barone M, Guizzardi M, Campanati B, Moroni M and Carabelli A. Platelet gel for healing cutaneous chronic wounds. *Transfus Apher Sci* 2004; 30: 145-51.
- [3] Simka M and Majewski E. The social and economic burden of venous leg ulcers: focus on the role of micronized purified flavonoid fraction adjuvant therapy. *Am J Clin Dermatol* 2003; 4: 573-81.
- [4] Feng J, Mineda K, Wu SH, Mashiko T, Doi K, Kuno S, Kinoshita K, Kanayama K, Asahi R, Sunaga A and Yoshimura K. An injectable non-cross-linked hyaluronic-acid gel containing therapeutic spheroids of human adipose-derived stem cells. *Sci Rep* 2017; 7: 1548.
- [5] Wu Y, Chen L, Scott PG and Tredget EE. Mesenchymal stem cells enhance wound healing through differentiation and angiogenesis. *Stem Cells* 2007; 25: 2648-59.
- [6] Kuo YR, Wang CT, Cheng JT, Wang FS, Chiang YC and Wang CJ. Bone marrow-derived mesenchymal stem cells enhanced diabetic wound healing through recruitment of tissue regeneration in a rat model of streptozotocin-induced diabetes. *Plast Reconstr Surg* 2011; 128: 872-80.
- [7] Sorice S, Rustad KC, Li AY and Gurtner GC. The role of stem cell therapeutics in wound healing: current understanding and future directions. *Plast Reconstr Surg* 2016; 138: 31S-41S.
- [8] Chen L, Tredget EE, Wu PY and Wu Y. Paracrine factors of mesenchymal stem cells recruit macrophages and endothelial lineage cells and enhance wound healing. *PLoS One* 2008; 3: e1886.
- [9] Rogers LC, Bevilacqua NJ and Armstrong DG. The use of marrow-derived stem cells to accelerate healing in chronic wounds. *Int Wound J* 2008; 5: 20-5.
- [10] Schubert T, Xhema D, Veriter S, Schubert M, Behets C, Delloye C, Gianello P and Dufrane D. The enhanced performance of bone allografts using osteogenic-differentiated adipose-derived mesenchymal stem cells. *Biomaterials* 2011; 32: 8880-91.
- [11] Veriter S, Aouassar N, Adnet PY, Paridaens MS, Stuckman C, Jordan B, Karroum O, Gallez B, Gianello P and Dufrane D. The impact of hyperglycemia and the presence of encapsulated islets on oxygenation within a bioartificial pancreas in the presence of mesenchymal stem cells in a diabetic wistar rat model. *Biomaterials* 2011; 32: 5945-56.

## Nanofat grafting combined with NPWT for chronic wounds

- [12] Carstens MH, Gomez A, Cortes R, Turner E, Perez C, Ocon M and Correa D. Non-reconstructable peripheral vascular disease of the lower extremity in ten patients treated with adipose-derived stromal vascular fraction cells. *Stem Cell Res* 2017; 18: 14-21.
- [13] Spiekman M, van Dongen JA, Willemsen JC, Hoppe DL, Van der Lei B and Harmsen MC. The power of fat and its adipose-derived stromal cells: emerging concepts for fibrotic scar treatment. *J Tissue Eng Regen Med* 2017; 11: 3220-35.
- [14] Yao Y, Dong Z, Liao Y, Zhang P, Ma J, Gao J and Lu F. Adipose extracellular matrix/stromal vascular fraction gel: a novel adipose tissue-derived injectable for stem cell therapy. *Plast Reconstr Surg* 2017; 139: 867-79.
- [15] Yoshimura K, Aoi N, Suga H, Inoue K, Eto H, Sato K, Kurita M, Harii K and Hirohi T. Ectopic fibrogenesis induced by transplantation of adipose-derived progenitor cell suspension immediately after lipoinjection. *Transplantation* 2008; 85: 1868-9.
- [16] Cheng NC, Wang S and Young TH. The influence of spheroid formation of human adipose-derived stem cells on chitosan films on stemness and differentiation capabilities. *Biomaterials* 2012; 33: 1748-58.
- [17] Park IS, Chung PS and Ahn JC. Enhanced angiogenic effect of adipose-derived stromal cell spheroid with low-level light therapy in hind limb ischemia mice. *Biomaterials* 2014; 35: 9280-9.
- [18] Piccolo NS, Piccolo MS and Piccolo MT. Fat grafting for treatment of burns, burn scars, and other difficult wounds. *Clin Plast Surg* 2015; 42: 263-83.
- [19] Kato H, Mineda K, Eto H, Doi K, Kuno S, Kinoshita K, Kanayama K and Yoshimura K. Degeneration, regeneration, and cicatrization after fat grafting: dynamic total tissue remodeling during the first 3 months. *Plast Reconstr Surg* 2014; 133: 303e-313e.
- [20] Dong Z, Peng Z, Chang Q, Zhan W, Zeng Z, Zhang S and Lu F. The angiogenic and adipogenic modes of adipose tissue after free fat grafting. *Plast Reconstr Surg* 2015; 135: 556e-567e.
- [21] Tonnard P, Verpaele A, Peeters G, Hamdi M, Cornelissen M and Declercq H. Nanofat grafting: basic research and clinical applications. *Plast Reconstr Surg* 2013; 132: 1017-26.
- [22] Kemaloglu CA. Nanofat grafting under a split-thickness skin graft for problematic wound management. *Springerplus* 2016; 5: 138.
- [23] Tamburino S, Lombardo GA, Tarico MS and Perrotta RE. The role of nanofat grafting in vulvar lichen sclerosus: a preliminary report. *Arch Plast Surg* 2016; 43: 93-5.
- [24] Mansoor J, Ellahi I, Junaid Z, Habib A and Ilyas U. Clinical evaluation of improvised gauze-based negative pressure wound therapy in military wounds. *Int Wound J* 2015; 12: 559-63.
- [25] Langer V, Bhandari PS, Rajagopalan S and Mukherjee MK. Negative pressure wound therapy as an adjunct in healing of chronic wounds. *Int Wound J* 2015; 12: 436-42.
- [26] Bovill E, Banwell PE, Teot L, Eriksson E, Song C, Mahoney J, Gustafsson R, Horch R, Deva A and Whitworth I. Topical negative pressure wound therapy: a review of its role and guidelines for its use in the management of acute wounds. *Int Wound J* 2008; 5: 511-29.
- [27] Banwell PE and Teot L. Topical negative pressure (TNP): the evolution of a novel wound therapy. *J Wound Care* 2003; 12: 22-8.
- [28] Armstrong DG and Lavery LA. Negative pressure wound therapy after partial diabetic foot amputation: a multicentre, randomised controlled trial. *Lancet* 2005; 366: 1704-10.
- [29] Hassan WU, Greiser U and Wang W. Role of adipose-derived stem cells in wound healing. *Wound Repair Regen* 2014; 22: 313-25.
- [30] Na YK, Ban JJ, Lee M, Im W and Kim M. Wound healing potential of adipose tissue stem cell extract. *Biochem Biophys Res Commun* 2017; 485: 30-4.
- [31] Sahin I, Ozturk S, Deveci M, Ural AU, Onguru O and Isik S. Experimental assessment of the neo-vascularisation of acellular dermal matrix in the wound bed pretreated with mesenchymal stem cell under subatmospheric pressure. *J Plast Reconstr Aesthet Surg* 2014; 67: 107-14.