




Micro-fragmentation is a valid alternative to cell expansion and enzymatic digestion of adipose tissue for the treatment of knee osteoarthritis: a comparative preclinical study

Giuseppe Filardo¹ · Matilde Tschon² · Francesco Perdisa³  · Silvia Brogini² · Carola Cavallo⁴ · Giovanna Desando⁴ · Gianluca Giavaresi² · Brunella Grigolo⁴ · Lucia Martini² · Nicolò Nicoli Aldini² · Alice Roffi¹ · Milena Fini² · Elizaveta Kon^{5,6}

Received: 21 April 2020 / Accepted: 11 November 2020

© European Society of Sports Traumatology, Knee Surgery, Arthroscopy (ESSKA) 2021

Abstract

Purpose The aim of this study was to compare three procedures to exploit adipose-derived cells for the treatment of osteoarthritis (OA) in a preclinical model, to understand their therapeutic potential and identify the most suitable approach for the clinical application.

Methods Biological samples from adipose tissue, processed by mechanical micro-fragmentation (MF), enzymatic digestion (SVF) or cell expansion (ADSCs), were first characterized in vitro and then used in vivo in a surgically induced OA rabbit model: Group 1—control group (untreated 12 knees/saline 12 knees), Group 2—MF (24 knees), Group 3—SVF (24 knees), Group 4—ADSCs (24 knees). Macroscopic, histological, histomorphometric, immunohistochemical and blood and synovial fluid analyses were evaluated at 2 and 4 months from the treatments.

Results Samples obtained by the three procedures yielded 85–95% of viable cells. In vivo assessments showed no significant side effects or inflammatory responses after the injection. The macroscopic Hanashi score did not show significant differences among treated groups and controls. The histopathological evaluation of synovial tissues showed lower signs of synovitis for MF, although the semiquantitative analysis (Krenn score) did not reach statistical significance. Instead, MF showed the best results both in terms of qualitative and semi-quantitative evaluations of articular cartilage, with a more uniform staining, a smoother surface and a significantly better Laverty score ($p = 0.004$).

Conclusion MF, SVF, and expanded ADSCs did not elicit significant local or systemic adverse reactions in this preclinical OA model. Among the different methods used to exploit the adipose tissue potential, MF showed the most promising findings in particular in terms of protection of the articular surface from the joint degenerative OA processes.

Level of evidence Preclinical animal study.

Keywords Osteoarthritis · Adipose-derived stromal cells · Micro-fragmentation · Enzymatic digestion · Adipose tissue · Knee

Giuseppe Filardo and Matilde Tschon equally contributed to this work.

Milena Fini and Elizaveta Kon equally contributed to this work.

Electronic supplementary material The online version of this article (<https://doi.org/10.1007/s00167-020-06373-y>) contains supplementary material, which is available to authorized users.

✉ Francesco Perdisa
dr.perdisa@gmail.com

Extended author information available on the last page of the article

Introduction

Osteoarthritis (OA) is a degenerative joint disease, characterized by progressive wear of the articular cartilage, subchondral bone changes, and synovial inflammation [22]. Innovative regenerative therapies aim at managing OA symptoms to delay more invasive surgeries, and at modifying the course of OA disease itself [14]. Among these, cell-based strategies are emerging, and mesenchymal stromal cells (MSCs) seem to hold promise [12, 15].

Adipose-derived mesenchymal stromal cells (ADSCs) are currently being investigated for OA treatment due to their

abundance and the ease of harvest and culture [35]. Preliminary studies showed promising findings with the use of in vitro expanded ADSCs, with improvement in knee pain and function, and some evidence of increased cartilage thickness [30]. However, prolonged cultivation is associated with an increased risk of cell transformation, with a decline in multipotency or alterations of genes involved in apoptosis and senescence [9, 16]. Moreover, this approach requires a two-step surgical procedure and the need for a Good Manufacturing Practice (GMP) cleanroom. Alternative approaches, such as enzymatic digested stromal vascular fraction (SVF) or mechanically micro-fragmented (MF) tissue have been developed to minimize cell manipulation [42], but they produce a heterogeneous cell population [24, 27, 33]. These different preparation procedures may entail specific regulatory requirements, which could affect the accessibility to this biological treatment approach for OA patients, and lead to different products in terms of biological composition and, probably, different clinical effects. As efforts to develop adipose-based treatment strategies are growing rapidly (103 trials registered in clinicalTrials.gov [7]), defining the most suitable approach is of utmost clinical relevance, as it could help focusing further clinical research in humans on the most effective procedure to address OA.

The aim of this experimental animal model study was to compare micro-fragmentation, enzymatic digestion, and ADSCs expansion to evaluate which biological approach is the most suitable as injective treatment for counteracting knee OA. The hypothesis of this study was that the different procedures used for obtaining adipose-derived cells could influence cell regenerative/repairative potential and consequently joint tissues degeneration in the OA rabbit model.

Materials and methods

Experimental design

This in vivo study was performed complying with the European and Italian Law on animal experiments, after the approvals of the research protocol by the Ethical Committee

and Animal Welfare Body of IRCCS Istituto Ortopedico Rizzoli and by the Italian Ministry of Health (authorization No. 862/2015-PR) in agreement with Italian (Legislative Decree 26/2014) and EU regulations. Directive 2010/63/EU on the protection of animals used for scientific purposes. This study was funded by the Italian Ministry of Health within the Project RF-2011–02352638.

Skeletally mature male New Zealand rabbits (Harlan Laboratories SRL, S. Pietro al Natisone, Udine) were housed in standard and controlled conditions.

Bilateral transection of the anterior cruciate ligament (ACL) [11, 29] was performed under general anesthesia to induce OA. Two months later, each knee received a single intra-articular (i.a.) injection according to treatment allocation: Group 1—control group (untreated 12 knees/saline 12 knees), Group 2—MF adipose tissue (24 knees), Group 3—SVF (24 knees), Group 4—expanded ADSCs (24 knees) (Table 1). Rabbits from all groups were euthanized at the scheduled experimental times of 2 and 4 months after treatment, to identify any possible differences in term of early and late effects of the treatment.

Adipose tissue harvesting and processing (details into Suppl. Materials section)

Autologous adipose tissue was harvested from the inguinal fat pad of each rabbit and processed to obtain MF, SVF, and expanded ADSCs for i.a. injections.

MF preparation

Due to the fibrotic nature of the rabbit tissue, adipose tissue was immediately minced under sterile conditions, to obtain proper consistency for the device processing. Then, the LIPOGEMS[®] system (Lipogems International, Milan, Italy) was used as a standard procedure. The final product was then collected into a syringe connected to the upper opening of the device. A volume of 300 µl of MF was injected into the OA knee joint.

Table 1 Experimental design: *n* indicates the number of rabbits used for the study

Group	Experimental times		Total rabbits (<i>n</i>)	
	2 months	4 months		
1	Control (<i>n</i> =6)	Control (<i>n</i> =6)	12	
	1a—Untreated 6 right knees	1b—0.9% NaCl 6 left knees	1a—Untreated 6 right knees	1b—0.9% NaCl 6 left knees
2	MF (<i>n</i> =6)	MF (<i>n</i> =6)	12	
3	SVF (<i>n</i> =6)	SVF (<i>n</i> =6)	12	
4	Expanded ADSCs (<i>n</i> =6)	Expanded ADSCs (<i>n</i> =6)	12	

SVF isolation

A cut-off of 10 cc of adipose tissue was established to standardize the samples for the SVF and lower biological samples variability. SVF, consisting of immune cells, endothelial cells (blood vessel lining), progenitors (undifferentiated or immature precursor cells) and stromal cells, was obtained following an enzymatic procedure, and centrifugation [2]. SVF was then washed and re-suspended with 300 μ l of saline solution for the i.a. injection in the OA knee joint.

ADSCs expansion

10 ml adipose tissue was harvested 2 weeks before the i.a. injection for the in vitro cell expansion. Similarly to SVF, ADSCs were obtained with an enzymatic treatment and then culture-expanded for two weeks. A total of 2×10^6 (cell density: 6.6×10^6 cells/ml) expanded ADSCs in 300 μ l saline solution was prepared upon sterile conditions for i.a. administration [11].

The same amount of adipose tissue was harvested also to obtain and set up the expanded ADSCs group to have the same starting condition for all groups and avoid any bias in evaluating the effectiveness of the different treatments. The remaining MF, SVF, and expanded ADSCs were evaluated in the laboratory for cell viability and phenotypic features (see Suppl. Materials).

Macroscopic, histological, histomorphometric, and immunohistochemical analyses

At the scheduled experimental times, the distal femoral epiphysis and synovia were retrieved from each knee joint. Gross appearance of the articular cartilage was examined through a macroscopic analysis, with the Hanashi score [18]: 0—surface smooth with normal colour; 1—surface rough with minimal fibrillation or a slight yellowish discoloration; 2—cartilage erosion extending into the superficial or middle layers; 3—cartilage erosion extending into deep layers; 4—complete cartilage erosion with subchondral bone exposure.

Explanted distal femoral condyles and synovial membranes were fixed in 10% neutral buffered formalin solution (Sigma-Aldrich, Saint Louis, Missouri, USA) for 48 h. Femoral specimens were decalcified in 5% solution of formic (ACEF, Fiumicino, Rome, Italy) and nitric acid (Sigma-Aldrich, Saint Louis, Missouri, USA) for about 20 days at 37 °C and paraffin-embedded. Serial sagittal sections of 5 μ m thickness were taken (microtome HM 340E; Carl Zeiss, Oberkochen, Germany). Femoral condyles were stained with 1.5% Safranin-O solution (Polysciences Inc., USA) and 0.02% Fast Green solution (Histo-Line Laboratories, Milano, Italy) and synovial membranes with

Hematoxylin/Eosin (Sigma-Aldrich, Saint Louis, Missouri, USA).

Krenn score was used for the assessment of synovial tissue; it considers three main features of synovitis: the enlargement of the synovial lining cells (single layer in healthy synovia but thickened if inflamed), the cellular density of the synovial stroma, and the density of the inflammatory infiltrate (non-resident cell population such as lymphocytes or plasma cells). It has a range from 0 to 9, from the absence (sum 0 or 1) to low grade (sum 2–4) or high-grade (sum 5–9) synovitis [20].

Finally, histomorphometric assessment of articular cartilage changes at the medial and lateral femoral condyles were evaluated with Laverty's grading system [21]. The score represents the sum of 4 different parameters: Safranin-O/Fast Green staining, articular cartilage structure, chondrocyte density and cluster formation. It has a possible maximum score of 24 points that translates to the worst OA scenario, and a minimum of 0, that translates to a normal and healthy articular cartilage.

Then, joints were processed for immunohistochemical analysis (Collagen II, MMP-1, TNF- α), and the peripheral blood and synovial fluid were collected for white blood cells count, as reported in detail in the Supplementary material.

Statistical analysis

Statistical analysis was performed using R v.3.6.2 software [37] and R packages 'ordinal' [6], 'emmean' [32], and 'hmisc' [13]. Ordinal data are presented as Median (Mdn) and minimum–maximum (Min–Max) range at a significant level of $p < 0.05$. Cumulative link mixed models (CLMM) were used to test if significant effects or interactions of fixed factors—'treatment', 'experimental time' and 'compartment'—on Hanashi macroscopic score, Krenn synovitis score and Laverty score were present. Pairwise comparisons of estimated marginal means were done to identify significant differences among groups; Sidak's adjusted p -values were calculated.

An a priori power analysis was done to define the sample size using the G*Power software (v. 3.1.9.2, Universität Kiel, Germany). By assuming an effect size $f \geq 0.40$ to detect significant differences in the histomorphometric score of Laverty with a power $1 - \beta = 0.90$ and $\alpha = 0.05$, a minimum number of 96 treated joints are needed ($n = 6$ animals for each group).

Results

Three rabbits originally foreseen for Group 3—SVF/2 months were moved to the Group 1—Control/2 months due to the low cellular yield from adipose tissue, bringing the sample size of

the Control group at 2 months to $n=9$. Three additional rabbits were performed in Group 3—SVF/2 months, to replace those moved. Animals reached the scheduled experimental times (2 and 4 months) without complications except for 5 rabbits of the Group 3—SVF at 4 months, due to: surgical extracapsular periarticular abscess of the knees (2 rabbits); inguinal abscess (2 rabbits) or a iatrogenic submandibular abscess (1 rabbit). The retrieved joints of these animals (except for the submandibular abscess) were not considered for the macroscopic and histological analyses. Then, of these 5 rabbits, 4 were replaced. For the different evaluations performed, no differences were seen between Group 1a Untreated and Group 1b 0.9% NaCl treated joints, which were merged as Control Group (Group 1-Control).

Further details on joints excluded from macroscopic and histological evaluations due to mainly technical problems are reported in the supplementary material.

Macroscopic analysis

No significant differences for Hanashi score were found among Treated Groups and Control Group, all showing macroscopic appearances of cartilage erosion extending from superficial into deep layers (Table 2). The Hanashi score of Group 3-SVF was significantly lower than that of Group 2-MF ($-27%$, $p=0.026$); experimental time factor had no significant effect on Hanashi score results.

Histological and histomorphometric analyses

The histopathological evaluation of synovial tissue, according to the Krenn synovitis score, showed signs of synovitis, particularly in Group 3—SVF and Group 4—expanded ADSCs in which 3 or more layers of lining cells, moderately

increased cellularity and inflammatory cells were found. In Group 1—Control, thickening of the synovial lining cells and an increase in cellularity of the stroma were noted, but without inflammatory infiltrates. The total Krenn score and sub-parameters did not show significant differences among Treated Groups and Control Groups (Table 3). Experimental time factor had no significant effects on Krenn score results.

The histopathological evaluation of cartilage tissue of the Group 1-Control at 2 months showed irregularities with fibrillation, fissures and matrix erosion (Fig. 1a). In some specimens, a widespread loss of cartilage matrix staining was observed, without thickening of the subchondral bone. At 4 months, severe OA with progressive loss of cartilaginous matrix was observed (Fig. 1b). At both experimental times, an improvement was observed following MF treatment (Fig. 1c, d), showing a more uniform cartilage staining and a smoother cartilage surface than the Control group. In the SVF group (Fig. 1e, f), surface irregularities with clefts and fibrillations were found, as well as low proteoglycans content. Furthermore, a multifocal decrease in cell density and the presence of clusters (Fig. 1e) were detected. At 4 months (Fig. 1f), SVF group reported fewer surface irregularities compared to the 2-month follow-up. In the expanded ADSCs group (Fig. 1g, h), some signs of surface irregularities were still evident at 4 months. An improvement in the cartilaginous matrix staining between the two experimental times was also noticed, but not in terms of cell density. In the statistical analysis of Laverty score results, when the results of treated Groups were compared to that of the control Group significant effects of ‘treatment’ and ‘compartment’ factors were detected (Table 4). In particular, the lowest Laverty score was found in Group 2-MF, resulting significantly better than Group 1-Control ($-28%$, $p=0.004$) (Table 4). Regardless of treatment, the Laverty score in the medial

Table 2 Results of Hanashi score (0–4) for each group and experimental time measured on joint surface of distal femoral epiphysis of both knees

Group		Experimental times	
		2 months	4 months
1-Control	Mdn, Min–Max	3, 1–4	2, 1–4
	(n = rabbits/n = joints)	(9/16)	(6/12)
2-MF	Mdn, Min–Max	3, 1–3	3, 2–4
	(n = rabbits/n = joints)	(5/9)	(6/12)
3-SVF*	Mdn, Min–Max	2, 1–4	2, 1–4
	(n = rabbits/n = joints)	(6/12)	(6/11)
4-Expanded ADSCs	Mdn, Min–Max	3, 2–4	3, 2–4
	(n = rabbits/n = joints)	(6/12)	(6/9)

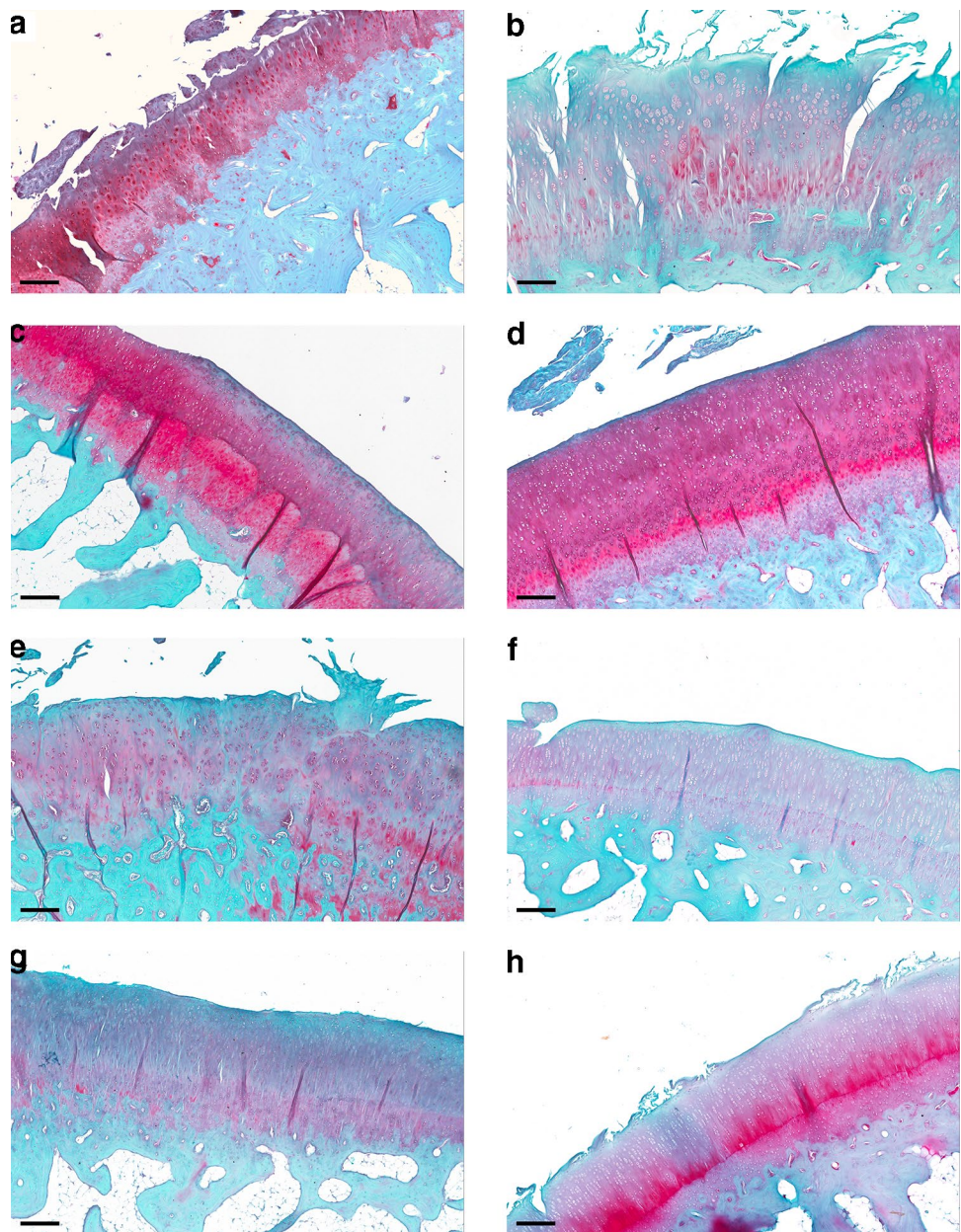
Mdn, Min–Max (n = rabbits/n = joints). The fitted CLMM model for repeated measures showed a significant effect of group factor ($\chi^2=8.65$, $p=0.034$). Pairwise comparisons: *, Group 3-SVF versus Group 2-MF ($p<0.05$)

Table 3 Results of Krenn synovitis score (0–9) for each group measured on the synovial membrane of both knee joints

Group		Experimental times	
		2 months	4 months
1-Control	Mdn, Min–Max	5, 4–7	3, 2–5
	(n = rabbits/n = joints)	(7/12)	(6/11)
2-MF	Mdn, Min–Max	6, 2–9	4, 2–5
	(n = rabbits/n = joints)	(5/9)	(6/11)
3-SVF	Mdn, Min–Max	5, 4–7	6, 5–8
	(n = rabbits/n = joints)	(6/11)	(5/9)
4-Expanded ADSCs	Mdn, Min–Max	5, 3–6	5, 4–6
	(n = rabbits/n = joints)	(6/11)	(6/9)

Mdn, Min–Max (n = rabbits/n = joints). The fitted CLMM model for repeated measures showed no significant effects or interactions of ‘treatment’ ($\chi^2=5.30$, $p=0.151$) and ‘experimental time’ ($\chi^2=0.728$, $p=0.393$) factors

Fig. 1 Representative histological images of femoral condyles untreated (**a, b**) and treated with MF (**c, d**), SVF (**e, f**), and expanded ADSCs (**g, h**), stained with Safranin-O/Fast Green at 2 (left column) and 4 (right column) months. Magnification 10X, scale bar: 200 μ m



femoral condyles was higher than that noted in the lateral femoral condyles (16%, $p = 0.008$). Concerning the single Laverty score sub-parameters, both 'staining' and 'structure' ones presented significantly higher scores in femoral medial condyles compared to lateral condyles of about 11% ($p = 0.014$) and 14% ($p = 0.041$), respectively. Group 2-MF presented better findings in terms of lower 'staining' score than Group 1-Control (-17% , $p = 0.060$) and Group 4-Expanded ADSCs (-18% , $p = 0.051$), even though the differences did not reach significant p -values.

No significant differences in terms of WBC of the peripheral blood or synovial fluid mucin content test were detected; further details, together with the *in vitro* cell assessment and

immunohistochemical analysis, are reported in the supplementary material.

Discussion

The main finding of this preclinical study is that MF adipose tissue showed more promising results in counteracting OA features in absence of side effects.

Adipose tissue is an abundant source of autologous ADSCs, responsible for the secretion of a wide variety of growth factors, cytokines, chemokines, and exosomes. These can influence surrounding progenitor cells and the entire microenvironment triggering repair mechanisms and

Table 4 Results of Lavery score (0–24) for each group measured on medial and lateral femoral condyles of both knee joints

Group		Experimental times	
		2 months	4 months
1-Control	Mdn, Min–Max (n=rabbits/n=joints)	15, 4–23 (9/31)	17, 9–23 (6/24)
2-MF**	Mdn, Min–Max (n=rabbits/n=joints)	12, 7–17 (5/19)	12, 6–20 (6/23)
3-SVF	Mdn, Min–Max (n=rabbits/n=joints)	16, 9–21 (6/24)	12, 7–20 (5/18)
4- Expanded ADSCs	Mdn, Min–Max (n=rabbits/n=joints)	13, 8–22 (6/22)	13, 7–21 (6/17)

Mdn, Min–Max (n=rabbits/n=joints). The fitted CLMM model for repeated measures showed significant effects of ‘treatment’ ($\chi^2=10.63$, $p=0.014$) and ‘compartment’ ($\chi^2=6.90$, $p=0.008$) factors. Pairwise comparisons: **, Group 2-MF *versus* Group 1-Control ($p<0.005$)

counteracting degenerative processes [3, 8], which could explain the positive findings observed. In view of these properties, the use of ADSCs for the treatment of musculoskeletal pathologies is rapidly increasing [30, 40], especially for the treatment of degenerative pathologies. Preclinical studies showed the safety, feasibility, and effectiveness of ADSCs application for the treatment of both focal and degenerative cartilage lesions, up to OA joints [11, 25, 30, 36, 38]. Moreover, clinical trials showed promising findings with the use of expanded ADSCs [30], and positive results have been also recorded for SVF and MF, indicating both safety and potential of these strategies, either as a pure injective approach or as an augmentation of surgical procedures for the treatment of OA [4, 19, 31, 34].

However, the majority of these clinical studies are case series, with heterogenous designs and without a direct comparison among different procedures, which makes difficult to understand the most suitable strategy to exploit their potential in counteracting symptoms and, possibly, the progression of OA. Indeed, ADSCs can be used not only as a homogenous population after expansion by culture. Cells can be also freshly isolated by the enzymatic digestion of adipose tissue, thus obtaining a heterogeneous SVF comprising various cell phenotypes at different degrees of differentiation, in which ADSCs represent up to 10%, as well as a pool of growth factors and cytokines [41]. More recently, a non-enzymatic mechanical technique has been developed to obtain a suspension of MF adipose tissue by minimal manipulation, thus preserving vascular/stromal architecture, and retaining elements with pericyte/perivascular identity significantly higher than in the lipoaspirate [1, 5, 39]. Both mechanical fragmentation and enzymatic digestion allow to avoid culture-expansion of cells and the related issues. SVF and MF contain ADSCs and their environment, the so-called

“niche”, which includes several cell types as well as a pool of cytokines and growth factors [1], shown to govern stem cells behaviour according to the body’s needs. However, these approaches differ from the regulatory point of view, as the production of SVF for clinical application is complicated by the need of adipose tissue enzymatic digestion with collagenase, a manipulation step that entails a more complicated path with the regulatory authorities [40]. Preliminary analyses were carried out to evaluate the biological features of adipose products before comparing their effects in the OA setting. SVF displayed a cell yield ranging from 7×10^5 to 10×10^5 nucleated cells per gram of adipose tissue. In this study, we were not able to perform cell count from the native untreated MF, which displayed a heterogeneous cell population entrapped in an extracellular matrix [10]. However, in a preliminary in vitro study a cell yield of 10^5 MF-ADSCs /0.1 gr of MF following enzymatic treatment was observed [28]. As for expanded-ADSCs, a cell concentration of 2×10^6 ADSCs/300 μ l was used, defined in a previous preclinical in vivo study, capable of promoting immunomodulatory, anti-inflammatory and anti-fibrotic effects [11]. All adipose products displayed good cell viability, high percentages of CD-90 and CD-146 and low positivity for the CD-45 marker.

The slightly better histological outcome in favour of MF would encourage the use of this approach, which obviates the need for GMPs facilities and expensive standard operating procedures required for extensive manipulation. Moreover, this procedure does not only imply lower costs and lower regulatory restrictions but also takes advantage of the effects of the entire “niche.” The positive results are in line with the in vitro study of Paoletta et al. [28] showing the ability of MF to reduce typical macrophages markers inducing specific inhibitors in an inflammatory model of OA synoviocytes [28]. MF produced low levels of inflammatory factors such as IL-6, CCL5/RANTES, CCL2/MCP-1, and CCL3/MIP-1 α , and a higher level only of CXC-chemokine ligand 8/IL 8 compared with expanded cells. Moreover, MF reduced the release of both macrophage-specific chemokines (CCL2/MCP-1 and CCL3/MIP-1 α) and degradative marker MMP-9, while increasing TIMP-1 (MMP-9 inhibitor) and down-modulating TLR4, key molecules of NF κ B pathways. Strictly dependent on TLR4 and NF κ B signalling, MF switched off macrophages activity [28]. On the other hand, in this preclinical rabbit model expanded-ADSC were only partially effective since the positive qualitative findings were not confirmed by the statistical analysis of the applied scores. These findings could be explained by the isolation procedure and culture conditions that could have interfered with their potential.

MF well preserves instead the stem cell “niche”, maintaining the biologically intact structure of cell–cell junctions and preserving the basal ECM proteins, which also showed to counteract inflammation [17]. MF also exhibited

greater levels of CD-163 marker, commonly expressed by wound-healing macrophages, than SVF and ADSCs, which could exert anti-inflammatory and repair activities directly on cartilage tissue. Moreover, the local biodistribution of MF, demonstrated at the synovial membrane level, may play a critical role in driving healing responses in this tissue at long-term follow-up [10]. These properties suggest MF potential to be applied to various inflammatory conditions or pathologies, such as OA, which requires to switch off macrophages with an inflammatory phenotype for adequate therapeutic treatment. In fact, synovitis is a common finding in OA joints, and synovial tissue may show significant changes, even before visible cartilage degeneration has occurred, with infiltration of mononuclear cells, thickening of the synovial lining layer and production of inflammatory cytokines [23]. Moreover, there is strong evidence that synovitis is associated with further worsening of OA [23], also augmenting the responsiveness of peripheral nociceptive neurons, and thereby contributing to increase the pain experience [26]. The potential of MF to address synovial inflammation is an important aspect to be considered for clinical application, where the symptomatic benefit is more likely linked to homeostatic rather than regenerative changes, and more studies are needed to understand how to further exploit this property.

A limitation of this study is the adaptation of a human micro-fragmentation procedure to process the rabbit adipose tissue, which presents more fibrotic characteristics. In fact, to permit the passage from syringe-to-device and back, the rabbit adipose tissue was minced under sterile condition before the mechanical fragmentation, to reduce it to a more homogenous compound. This additional passage could have affected the potential of MF and possibly reduced the effects on the joint tissues. Nonetheless, the direct comparison of the efficacy of three procedures to isolate ADSCs within the same well-established animal model of OA has never been investigated. As regards the effect on the statistical analysis of having moved rabbits from Group 3-SVF to Group 1-Control, as well as of excluding for technical problems some bone segments from histology and histomorphometry, a post hoc power analysis on primary outcome confirmed that the statistical analysis carried out with the modified sample size was adequate (Laverty score: $1-\beta \approx 0.93$).

Results were slightly in favour of MF, although several other aspects remain to be clarified to optimize the potential of ADSCs application for the treatment of degenerative joint pathologies. However, while further studies should aim at better understanding the mechanism of action, as well as potential and limitations of this treatment, this study provides preliminary insights on their promising effects in cartilage. All experimental treatments did not elicit significant adverse reactions, with peripheral blood and synovial WBC contents supporting the safety of all the examined

treatments. Thus, taking into account these preclinical findings, as well as the minimally manipulated procedure in a closed system, MF can be considered a suitable strategy to exploit ADSCs potential as a minimally invasive treatment in the clinical practice. High-level studies in humans should explore and confirm the potential of MF injections to provide a significant clinical benefit and to slow down the degeneration processes in patients affected by knee OA.

Conclusion

MF, SVF, and expanded ADSCs did not elicit significant local or systemic adverse reactions in this preclinical OA model. Among these different strategies to exploit the adipose tissue potential, MF showed the most promising findings in particular in terms of protection of the articular surface from the joint degenerative processes. While the use of adipose tissue-derived procedures produced positive overall results in the present OA animal model, some aspects remain to be clarified, such as the identification of the best application protocol and of the patients and OA phase that could benefit more from this treatment. MF showed promising preliminary evidence as a minimally invasive injective treatment to address knee OA.

Funding This study was funded by the Project “Adipose-derived mesenchymal stem cells as a new minimally invasive regenerative treatment to target early osteoarthritis: from preclinical procedure selection to clinical application in a randomised double-blinded controlled trial” (project code: RF-2011–02352638).

Compliance with ethical standards

Conflict of interest All Authors confirm they have no Conflict of interests related to the present paper.

Ethical approval This in vivo study was performed complying with the European and Italian Law on animal experiments, after the approvals of the research protocol by the Ethical Committee and Animal Welfare Body of IRCCS Istituto Ortopedico Rizzoli and by the Italian Ministry of Health (Authorization No. 862/2015-PR) in agreement with Italian (Legislative Decree 26/2014) and EU regulations (Directive 2010/63/EU on the protection of animals used for scientific purposes).

References


1. Bianchi F, Maioli M, Leonardi E, Olivi E, Pasquinelli G, Valente S, Mendez AJ, Ricordi C, Raffaini M, Tremolada C, Ventura C (2013) A new nonenzymatic method and device to obtain a fat tissue derivative highly enriched in pericyte-like elements by

- mild mechanical forces from human lipoaspirates. *Cell Transplant* 22:2063–2077
2. Bora P, Majumdar AS (2017) Adipose tissue-derived stromal vascular fraction in regenerative medicine: a brief review on biology and translation. *Stem Cell Res Ther* 8:145
 3. Caplan AI, Dennis JE (2006) Mesenchymal stem cells as trophic mediators. *J Cell Biochem* 98:1076–1084
 4. Cattaneo G, De Caro A, Napoli F, Chiapale D, Trada P, Camera A (2018) Micro-fragmented adipose tissue injection associated with arthroscopic procedures in patients with symptomatic knee osteoarthritis. *BMC Musculoskelet Disord* 19:176
 5. Ceserani V, Ferri A, Berenzi A, Benetti A, Ciusani E, Pascucci L, Bazzucchi C, Cocce V, Bonomi A, Pessina A, Ghezzi E, Zeira O, Ceccarelli P, Versari S, Tremolada C, Alessandri G (2016) Angiogenic and anti-inflammatory properties of micro-fragmented fat tissue and its derived mesenchymal stromal cells. *Vasc Cell* 8:3
 6. Christensen R (2019) Ordinal—regression models for ordinal data.
 7. Chu DT, Nguyen Thi Phuong T, Tien NLB, Tran DK, Minh LB, Thanh VV, Gia Anh P, Pham VH, Thi Nga V (2019) Adipose tissue stem cells for therapy: an update on the progress of isolation, culture, storage, and clinical application. *J Clin Med* 8:917
 8. D'Arrigo D, Roffi A, Cucchiari M, Moretti M, Candrian C, Filardo G (2019) Secretome and extracellular vesicles as new biological therapies for knee osteoarthritis: a systematic review. *J Clin Med* 8:1867
 9. Danisovic L, Oravcova L, Krajcivova L, Varchulova Novakova Z, Bohac M, Varga I, Vojtassak J (2017) Effect of long-term culture on the biological and morphological characteristics of human adipose tissue-derived stem Cells. *J Physiol Pharmacol* 68:149–158
 10. Desando G, Bartolotti I, Martini L, Giavaresi G, Nicoli Aldini N, Fini M, Roffi A, Perdisa F, Filardo G, Kon E, Grigolo B (2019) Regenerative features of adipose tissue for osteoarthritis treatment in a rabbit model: enzymatic digestion versus mechanical disruption. *Int J Mol Sci* 20:2636
 11. Desando G, Cavallo C, Sartoni F, Martini L, Parrilli A, Veronesi F, Fini M, Giardino R, Facchini A, Grigolo B (2013) Intra-articular delivery of adipose derived stromal cells attenuates osteoarthritis progression in an experimental rabbit model. *Arthritis Res Ther* 15:R22
 12. Dimarino AM, Caplan AI, Bonfield TL (2013) Mesenchymal stem cells in tissue repair. *Front Immunol* 4:201
 13. Fe H (2020) Hmisc: A package of miscellaneous R functions.
 14. Filardo G, Kon E, Longo UG, Madry H, Marchettini P, Marmotti A, Van Assche D, Zanon G, Peretti GM (2016) Non-surgical treatments for the management of early osteoarthritis. *Knee Surg Sports Traumatol Arthrosc* 24:1775–1785
 15. Filardo G, Perdisa F, Roffi A, Marcacci M, Kon E (2016) Stem cells in articular cartilage regeneration. *J Orthop Surg Res* 11:42
 16. Froelich K, Mickler J, Steusloff G, Technau A, Ramos Tirado M, Scherzed A, Hackenberg S, Radeloff A, Hagen R, Kleinsasser N (2013) Chromosomal aberrations and deoxyribonucleic acid single-strand breaks in adipose-derived stem cells during long-term expansion in vitro. *Cytotherapy* 15:767–781
 17. Hamdi H, Planat-Benard V, Bel A, Puymirat E, Geha R, Pidial L, Nematalla H, Bellamy V, Bouaziz P, Peyrard S, Casteilla L, Brunelval P, Hagege AA, Agbulut O, Menasche P (2011) Epicardial adipose stem cell sheets results in greater post-infarction survival than intramyocardial injections. *Cardiovasc Res* 91:483–491
 18. Hanashi D, Koshino T, Uesugi M, Saito T (2002) Effect of femoral nerve resection on progression of cartilage degeneration induced by anterior cruciate ligament transection in rabbits. *J Orthop Sci* 7:672–676
 19. Hong Z, Chen J, Zhang S, Zhao C, Bi M, Chen X, Bi Q (2019) Intra-articular injection of autologous adipose-derived stromal vascular fractions for knee osteoarthritis: a double-blind randomized self-controlled trial. *Int Orthop* 43:1123–1134
 20. Krenn V, Morawietz L, Burmester GR, Kinne RW, Mueller-Ladner U, Muller B, Haupl T (2006) Synovitis score: discrimination between chronic low-grade and high-grade synovitis. *Histopathology* 49:358–364
 21. Laverty S, Girard CA, Williams JM, Hunziker EB, Pritzker KP (2010) The OARSI histopathology initiative—recommendations for histological assessments of osteoarthritis in the rabbit. *Osteoarthritis Cartilage* 18(Suppl 3):S53–65
 22. Loeser RF, Goldring SR, Scanzello CR, Goldring MB (2012) Osteoarthritis: a disease of the joint as an organ. *Arthritis Rheum* 64:1697–1707
 23. Mathiessen A, Conaghan PG (2017) Synovitis in osteoarthritis: current understanding with therapeutic implications. *Arthritis Res Ther* 19:18
 24. Mehranfar S, Abdi Rad I, Mostafav E, Akbarzadeh A (2019) The use of stromal vascular fraction (SVF), platelet-rich plasma (PRP) and stem cells in the treatment of osteoarthritis: an overview of clinical trials. *Artif Cells Nanomed Biotechnol* 47:882–890
 25. Mei L, Shen B, Ling P, Liu S, Xue J, Liu F, Shao H, Chen J, Ma A, Liu X (2017) Culture-expanded allogenic adipose tissue-derived stem cells attenuate cartilage degeneration in an experimental rat osteoarthritis model. *PLoS ONE* 12:e0176107
 26. Neogi T, Guermazi A, Roemer F, Nevitt MC, Scholz J, Arendt-Nielsen L, Woolf C, Niu J, Bradley LA, Quinn E, Law LF (2016) Association of Joint Inflammation With Pain Sensitization in Knee Osteoarthritis: The Multicenter Osteoarthritis Study. *Arthritis Rheumatol* 68:654–661
 27. Panchal J, Malanga G, Sheinkop M (2018) Safety and Efficacy of Percutaneous Injection of Lipogems Micro-Fractured Adipose Tissue for Osteoarthritic Knees. *Am J Orthop*. <https://doi.org/10.12788/ajo.2018.0098>
 28. Paolella F, Manferdini C, Gabusi E, Gambari L, Filardo G, Kon E, Mariani E, Lisignoli G (2019) Effect of microfragmented adipose tissue on osteoarthritic synovial macrophage factors. *J Cell Physiol* 234:5044–5055
 29. Parrilli A, Giavaresi G, Ferrari A, Salamanna F, Desando G, Grigolo B, Martini L, Fini M (2017) Subchondral bone response to injected adipose-derived stromal cells for treating osteoarthritis using an experimental rabbit model. *Biotech Histochem* 92:201–211
 30. Perdisa F, Gostynska N, Roffi A, Filardo G, Marcacci M, Kon E (2015) Adipose-derived mesenchymal stem cells for the treatment of articular cartilage: a systematic review on preclinical and clinical evidence. *Stem Cells Int* 2015:597652
 31. Pers YM, Rackwitz L, Ferreira R, Pullig O, Delfour C, Barry F, Sensebe L, Casteilla L, Fleury S, Bourin P, Noel D, Canovas F, Cyteval C, Lisignoli G, Schrauth J, Haddad D, Domergue S, Noeth U, Jorgensen C, Consortium A (2016) Adipose mesenchymal stromal cell-based therapy for severe osteoarthritis of the knee: a phase I dose-escalation trial. *Stem Cells Transl Med* 5:847–856
 32. Lenth R, Singmann H, Love J, Buerkner P, Herve M (2019) Estimated marginal means, aka least-squares means.
 33. Roato I, Belisario DC, Compagno M, Lena A, Bistolfi A, Maccari L, Mussano F, Genova T, Godio L, Perale G, Formica M, Cambieri I, Castagnoli C, Robba T, Felli L, Ferracini R (2019) Concentrated adipose tissue infusion for the treatment of knee osteoarthritis: clinical and histological observations. *Int Orthop* 43:15–23
 34. Russo A, Screpis D, Di Donato SL, Bonetti S, Piovano G, Zorzi C (2018) Autologous micro-fragmented adipose tissue for the treatment of diffuse degenerative knee osteoarthritis: an update at 3 year follow-up. *J Exp Orthop* 5:52

35. Si Z, Wang X, Sun C, Kang Y, Xu J, Wang X, Hui Y (2019) Adipose-derived stem cells: Sources, potency, and implications for regenerative therapies. *Biomed Pharmacother* 114:108765
36. Srzentic Drazilov S, Mrkovacki J, Spasovski V, Fazlagic A, Pavlovic S, Nikcevic G (2018) The use of canine mesenchymal stem cells for the autologous treatment of osteoarthritis. *Acta Vet Hung* 66:376–389
37. Team RC (2019) R: A language and environment for statistical computing. R Foundation for Statistical Computing, Vienna, Austria
38. Toghraie FS, Chenari N, Gholipour MA, Faghih Z, Torabinejad S, Deghani S, Ghaderi A (2011) Treatment of osteoarthritis with infrapatellar fat pad derived mesenchymal stem cells in Rabbit. *Knee* 18:71–75
39. Tremolada C, Colombo V, Ventura C (2016) Adipose tissue and mesenchymal stem cells: state of the art and lipogems(R) technology development. *Curr Stem Cell Rep* 2:304–312
40. Whitney KE, Liebowitz A, Bolia IK, Chahla J, Ravuri S, Evans TA, Philippon MJ, Huard J (2017) Current perspectives on biological approaches for osteoarthritis. *Ann N Y Acad Sci* 1410:26–43
41. Yoshimura K, Shigeura T, Matsumoto D, Sato T, Takaki Y, Aiba-Kojima E, Sato K, Inoue K, Nagase T, Koshima I, Gonda K (2006) Characterization of freshly isolated and cultured cells derived from the fatty and fluid portions of liposuction aspirates. *J Cell Physiol* 208:64–76
42. Zhu M, Cohen SR, Hicok KC, Shanahan RK, Strem BM, Yu JC, Arm DM, Fraser JK (2013) Comparison of three different fat graft preparation methods: gravity separation, centrifugation, and simultaneous washing with filtration in a closed system. *Plast Reconstr Surg* 131:873–880

Publisher's Note Springer Nature remains neutral with regard to jurisdictional claims in published maps and institutional affiliations.

Authors and Affiliations

Giuseppe Filardo¹ · Matilde Tschon² · Francesco Perdisa³  · Silvia Brogini² · Carola Cavallo⁴ · Giovanna Desando⁴ · Gianluca Giavaresi² · Brunella Grigolo⁴ · Lucia Martini² · Nicolò Nicoli Aldini² · Alice Roffi¹ · Milena Fini² · Elizaveta Kon^{5,6}

¹ Applied and Translational Research Center, IRCCS Istituto Ortopedico Rizzoli, Via di Barbiano 1/10, Bologna, Italy

² Surgical Sciences and Technologies, IRCCS Istituto Ortopedico Rizzoli, Via di Barbiano 1/10, Bologna, Italy

³ SC Chirurgia Protesica e dei Reimpianti d'Anca e di Ginocchio, IRCCS Istituto Ortopedico Rizzoli, Via Pupilli 2, 40136 Bologna, Italy

⁴ Laboratorio RAMSES, IRCCS Istituto Ortopedico Rizzoli, Via di Barbiano 1/10, Bologna, Italy

⁵ Department of Biomedical Sciences, Humanitas University, Via Rita Levi Montalcini 4, 20090 Pieve Emanuele, Milan, Italy

⁶ Humanitas Clinical and Research Center - IRCCS, Via Manzoni 56, Rozzano, 20089 Milan, Italy