

A new treatment of genito-urinary post-menopausal atrophy with autologous micro-fragmented fat tissue: a thirty-six months follow up case series

G. CASAROTTI^{1,2}, C. TREMOLADA^{2,3}

¹Ob/Gyn Specialist, Milan, Italy

²Image Institute, Milan, Italy

³Manchester Metropolitan University, Manchester, UK

Abstract. – **OBJECTIVE:** Genitourinary atrophy is a menopausal pathological change determined by the definitive drop of ovarian hormones' production that can impact heavily on the health status of women, with important direct and indirect social costs. Unfortunately, available treatments are only symptomatic, and they are not able to reverse the atrophy and other related symptoms. Regenerative medicine, with single local injection of autologous micro-fractured fat tissue, could represent a viable new solution for these patients as it not only helps to relieve symptoms, but it also counteracts the mechanisms that lead to the menopausal genitourinary atrophy. The objective of this paper is to evaluate the long-term effectiveness of micro-fractured fat vulvar injection for genito-urinary atrophy in patients, affected by severe genitourinary atrophy (at least 4 symptoms lasting for at least 4 years).

PATIENTS AND METHODS: We present a case series of 35 patients followed for 36 months to evaluate the effectiveness and safety of a single subcutaneous vulvar injection of autologous micro-fragmented fat tissue (MFAT).

RESULTS: We have not observed any adverse effects in any patients. All symptoms, and especially pelvic pain and dyspareunia, improved in almost half of patients within 3 months. Ninety-nine percent of patients recovered completely from all symptoms after 9-12 months, reporting no relapse of the symptoms up to the third year of follow up.

CONCLUSIONS: Our case series is the first case series, evaluating the long-term (3 years) safety and effectiveness of micro-fragmented adipose tissue graft for urogenital atrophy.

Key Words:

Micro-fragmented fat tissue, Genitourinary atrophy, Vaginal atrophy, Menopause, Regenerative medicine, Pelvic pain, Lipogems.

Introduction

It is well known that genitourinary atrophy is a menopausal pathological change determined by the definitive drop of ovarian hormones' production¹.

After estrogen's depletion, the vagina suffers several trophic changes that negatively impact on the morphological-functional characteristics typical of fertile age¹. Fornixes and wrinkles of the walls disappear, while the vaginal canal assumes a tubular shape. Furthermore, all vaginal subcutaneous layers are affected by morphological involution with loss of elastic fibers reducing the vagina's elasticity and lubrication². Also, the urethra, which has the same embryonic origin as the vagina, goes into the same involution process with reduction of the superficial squamous cells, thinning of the muscular layer and reduction of the vascular submucosal plexus².

These morphological changes often result in vaginal dryness, dyspareunia and burning pain. The glycogen reduction leads also to decreased lactic acid concentrations with an increase in pH leading to local dysbiosis responsible for chronic vaginitis and cystitis³. Finally, the weakening of urethral muscular tract decreases the intra-urethral pressure, favoring urinary incontinence¹.

Studies, presented during the World Menopause Day, underlined how urinary atrophy is one of the most important causes of discomfort and reduced quality in women in postmenopausal age⁴. A large-scale European study evaluated how symptoms related to atrophy of the genitourinary system also negatively affected mood, mental and sexual well-being, self-esteem, the joy of living and working ability⁵.

Even though hormonal replacement therapy (HRT) is the gold standard therapy for counteracting urinary genital atrophy, it is commonly poorly used, also because it only provides a symptomatic effect⁶⁻⁸ whereby, as soon as it is stopped, the involution process reoccurs. It has been estimated that only 25% of the female menopausal population uses hormones, while the other are looking for alternative therapies without significant benefits and with increased social and health direct and indirect costs⁶, such as increased antibiotic use for treatment of genitourinary infections and increased number of emergency services admissions for acute pain and of medical consultations and interventions for chronic pain⁹.

Vaginal atrophy can also cause spontaneous and post-coital bleeding, increasing not only the impairment of quality of life but also women's concerns, and requiring physicians to ask for unnecessary and costly analysis. Furthermore, these women commonly require the use of devices to control incontinence problems¹⁰.

In recent years, regenerative medicine techniques, such as mesenchymal stem cells or autologous fat tissue, have been proven effective for the management not only in several chronic degenerative and inflammatory diseases, but also in all problems related to aging frailty¹¹. In fact, autologous mechanically fragmented adipose tissue has characterized by small adipose clusters with presence of intact small vessels and perivascular niche¹¹. This "tissue" has great regenerative potential for their secretome activity in grow factor and cytokines involved in anti-inflammatory activity, tissue reparation, and regenerative activation. Hence, the autologous micro fragmented fat tissue has superior activity of enzymatically derived mesenchymal cells as their increased content in pericytes with increased paracrine regenerative activity¹². Hence, Mesenchymal Stem Cells (MSCs) derived from micro-fragmented adipose tissue (MFAT) obtained with the Lipogems[®] technique appear to have a strong antiinflammatory and regenerative capability^{13,14}. Furthermore, a recent study¹⁵ in a rat menopausal model has well described immune-histochemical and histological changes obtained with adipose derived mesenchymal stem cells.

Based on this knowledge, they could be helpful also in reversing the atrophic evolution of the vagina and urethra, as showed in our previous case reports¹⁶. In our paper¹⁶ we have showed the effectiveness of MFAT in the treatment of three women with postmenopausal atrophy. All patients

have shown long-term (3 years) improvement of clinical symptoms, restoration of acid pH with reduction in the risk of infection and concomitant histological changes, such as increased vascularity of submucosal tissue and thickening of the vagina's epithelium.

Unfortunately, to our knowledge, there is no any other study about this viable therapeutic opportunity except a phase 2 pilot study with platelet riched plasma associated with hyaluronic acid in 20 patients with postmenopausal vulvo-vaginal atrophy in women with history of breast cancer¹⁷.

The objective of this case series is to present a 3 year follow up case series of all 35 consecutive patients treated after their first three patients, from 2012 to 2016 in order to eventually confirm former previous results in the first small cohort.

Patients and Methods

In this descriptive case series, we present an analysis of 35 patients with disorders related to genitourinary atrophy treated with micro-fragmented fat tissue (Lipogems[™], Milan, Italy). As it is a case series of our clinical practice with anonymized data, we have not asked for Ethical Committee permission. All patients signed an informed consent to approve the use of their anonymized data for research purposes.

Inclusion criteria: according to our clinical practice we have selected for this treatment patients with postmenopausal (physiological or pharmacologically-induced) genito-urinary atrophy, in menopause at least for a minimum of four years, who had never taken HRT or used local estrogens and who have had severe clinical symptoms with at least four of the following signs: dyspareunia, vaginal dryness, burning, itching, decreased sensitivity, recurrent vaginitis, recurrent cystitis, stinging-bladder tenesmus, mild-moderate-severe stress urinary incontinence. All patients were complaining these symptoms since at least 4 years,

We have not included patients with cancer or with other disease that required surgery or other specific interventions.

All patients were classified, on a clinical basis in three classes: severe symptoms, moderate symptoms, mild symptoms, asymptomatic patients.

In our daily clinical activity at the baseline assessment we evaluated how long the symptoms have been present, if they were spontaneous or

provoked, and if they were related to sexual activity. Women were also asked to classify them as mild, moderate, or severe.

In sexually active women dyspareunia was classified using the pain scale NRS (Numerical Rate Scale) from 0 (absent pain) to 10 (most severe pain). According to worldwide classification, we divided pain into 4 classes: no pain (0), mild (1-3), moderate (4-6), severe (7-10). We registered pain area on a specific picture of the vulva-vaginal area (Venus, large right and left lip, urethral meatus, prepuce, clitoris, frenulum, vestibule, small left and right lip, hymen, navicular fossa, fork).

Vaginal and clitoral sensitivity was classified as normal, reduced, or very reduced.

Stress urinary incontinence (IUS) was evaluated with the Q-tip Test to evaluate motility of the urethra after coughing.

In our clinical practice we routinely followed patients at 6, 12, 24 and 36 months after the procedure and in addition, whenever patients have a specific need.

The procedure for harvesting of the adipose tissue and Lipogems (Milan, Italy) preparation was the same already described in our previous article¹². The surgical procedure was performed in local anesthesia. Autologous adipose tissue was harvested from the lateral or lower abdomen after injection of 100 ml of Klein solution. Harvested fat was immediately processed and micro fragmented with a closed system kit (Lipogems, Milan, Italy) in order to obtain MFAT. The device mechanically isolates and produces micro fractured adipose fat tissue, without destroying perivascular niche and in the meantime eliminating all the oil and the pro-inflammatory cytokines. It

can lead to 15 mL of MFAT from 120 of harvested fat tissue. Then, the solution is injected, with a 19G blunt cannula, in all sub-mucosal tissues of the anterior vagina with special regard to painful areas.

Statistical Analysis

We present only descriptive analysis as it is a case series. Hence, no statistical analysis was performed. All data at follow-up showing percentage of patients with severe, mild or absence of the symptom were considered.

Results

Thirty-five patients (42-66 years old) with at least four symptoms among those described in the methods section, since at least 4 years have been treated and have a follow up of at least 3 years (Table I).

Considering all the symptoms (Figure 1) before treatment we have 20 patients (57%) classified as severe and 15 (43%) patients classified as moderate. At 6 months no patients described persistence of severe symptoms, and 19 patients (54%) had only mild symptoms. At one year 5 patients (15%) had mild symptoms and all other patients (85%) declared themselves asymptomatic. At two and three years only 3 patients (8%) described having mild symptoms.

Dyspareunia (Figure 2) was indicated by 32 (91%) patients (3 patients did not describe sexual activity); ten patients had moderate pain and twenty-two patients' severe pain. At six months 9 patients described having moderate pain and 23 patients' mild pain. After one year, one patient

Table I. Frequency of symptoms at the enrollment of patients.

Symptom	Number of patients/35 patients	Severe	Moderate or mild
Dyspareunia	32/35	22	10
Dryness	35/35	20	15
Burning	35/35	32	3
Itching	35/35	32	3
Vaginitis/Cystitis	8/35		
Stranguria	20/35		
Incontinence	12/35	3	9

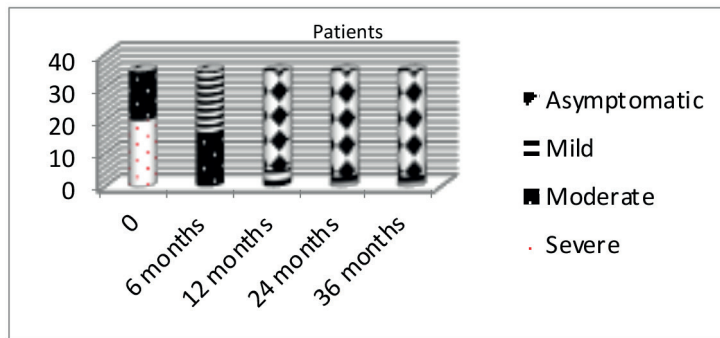


Figure 1. Distribution of all symptoms at different follow up.

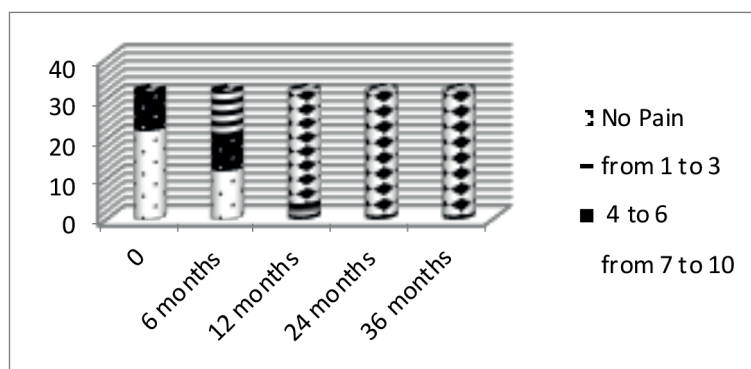


Figure 2. Dyspareunia over the time in 32 patients.

complained of moderate pain, 3 patients' mild pain and 28 patients were asymptomatic. At two and three years only one patient still described moderate pain while all the others were asymptomatic.

Stranguria and bladder tenesmus was felt by 20 (57%) women (Figure 3). The stranguria and the bladder tenesmus, reported by these 20 women, rapidly decreased, following treatment, disappearing completely by the 12th month.

Stress urinary incontinence was present in 12

cases (Figure 4) and classified as severe in 3 women, moderate in 7 women and mild in 2 women. Severe stress urinary incontinence slightly improved in 2 patients after 6 months. The 7 women with moderate IUS and the two with a mild form, no longer had loss of urine after 36 months.

All patients described dryness (18 moderate and 17 severe), burning and itching. Among 15 women with moderate dryness, symptoms completely disappeared after 12 months. Among the patients with symptoms of severe dryness, this completely

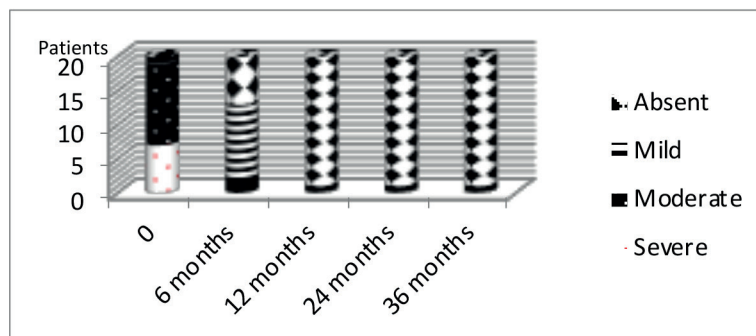


Figure 3. Stranguria and bladder tenesmus over the time in 20 patients.

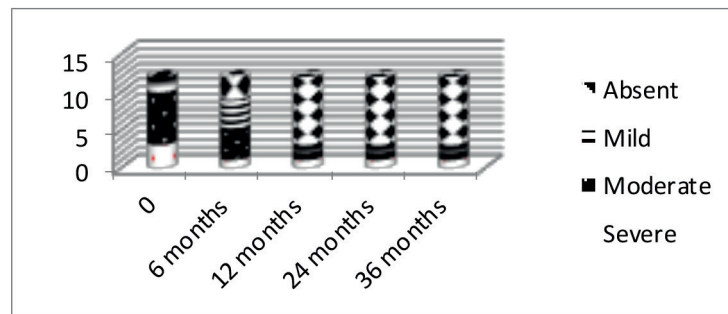


Figure 4. Urine incontinency over the time in 12 patients.

disappeared in 30 patients at 12 months and the results were maintained up to 36 months. Only in two patients' symptoms continued but were described as being mild. Burning and itching disappeared in all patients after 12 months.

Twenty (57%) patients had a severe impairment of vaginal sensitivity. All the twenty women with abnormal clitoral and/or vaginal sensitivity demonstrated complete recovery after 3 months; the relief remained up to the end of the study (36 months). In four patients it was also reported that orgasm was reached more quickly and with more satisfaction for all of the periods evaluated.

Eight patients (23%) had more than 4 episodes of bacterial cystitis or vaginitis per year. Five patients with previous recurrent vaginitis and cystitis (more than 4 episodes per year) no longer suffered these infections, two women had only one episode in the first two years and one patient showed no improvement.

Notably, in all patients the vaginal swabs performed at 36 months showed a normal vaginal saprophytic flora and a physiological pH.

Discussion

Micro-fragmented adipose tissue (MFAT) has shown in both *in vitro* and animal experiments its anti-inflammatory and regenerative properties^{18,19}, also in a rat menopausal model. Furthermore, MFAT has displayed in cellular experiments more anti-inflammatory activity than enzymatically derived stromal vascular fraction as it contains more pericytes cells that are responsible for the modulation of immune (especially NK cells that are strictly related to chronic pain) and inflammatory response¹³. In fact, the total amount of cytokines secreted by lipoaspirate appears to decrease much more rapidly than those secreted by MFAT culture. Furthermore, MFAT seems to

inhibit inflammation for a longer time compared to lipoaspirate¹³.

As discussed in the background, genitourinary atrophy is a common condition in postmenopausal women that can cause several different clinical problems affecting patients' outcome and causing several direct and indirect costs⁹. Symptoms associated to genitourinary atrophy are related to an involutivity process of subcutaneous tissue and to a chronic inflammation that has no ability to restore the normal physiological conditions. Unfortunately, up to now there were no therapeutic options that could counteract these processes and current therapy is only capable of reducing the symptoms².

Theoretically, MSC and secretome obtained from MFAT have all the properties to regenerate the atrophied tissue modulating also the associated chronic inflammation. Recently, some authors have demonstrated how human adipose-derived stem cells could improve mucosal atrophy improving symptoms and local inflammation^{19,20} and rat model has demonstrated the histological changes induced by local injection of adipose derived mesenchymal stem cells¹⁵.

Based on this background, in 2012 we have started to treat patients with symptomatic genitourinary atrophy with MFAT, using the Lipogems[®] technique generating important results also from a histopathological point of view¹⁶. According with the results obtained by Kasap et al¹⁵ in 2019, in 2014 we have already observed also a recovery of vaginal atrophy with new production of glycogen, vasculature hyperplasia and regeneration of the epithelium and subcutaneous tissue maintained up to 36 months¹⁶.

Unfortunately, after this first case series no any other study has been published. Hence, we have decided to present the entire case series of all patients treated in our centers, in order to better understand the long-term treatment success

and safety in a larger population of patients. We have treated patients with chronic pain and severe symptoms, related to genitourinary atrophy, that were present at least from 4 years. All patients enrolled were considered poorly responsive to “classical” treatments and we have treated only patients suffering from several symptoms (at least 4 symptoms in the same time) for a minimum of 4 years. Furthermore, none of these patients received any HRT for their symptoms.

Regarding safety, we confirm our previous results, as we have not observed any adverse effect in any of the patients. The surgical procedure, performed following local anesthesia, was very well tolerated. Finally, we have not registered any surgical complication nor any short-term and long-term problems in the area where we have harvested the fat tissue.

Interestingly, we also indicate that it is necessary to wait for some months in order to have a complete recovery of the symptoms. In fact, we registered an almost complete reduction of the symptoms in the majority of patients at 6-9 months, with a complete resolution of all symptoms at one year. It is important to explain to the patients the timeline of recovery, when this therapeutic option is discussed in order to improve their adherence to the therapy. Interestingly, we have succeeded to follow-up the patients selected.

Notably, the clinical results are maintained up to 3 years in all patients except for one. The single patient who did not respond to the MFAT treatment, suffered severe vaginal injuries during a dystocic delivery with loss of vaginal tissue; despite two plastic reconstructive interventions, she had a structural vulvar-vaginal alteration with extensive areas of fibrotic tissue and stenosis due to scar retraction. She had a second treatment after 14 months with only slight (NRS 5-6) reduction of the pain at the 24th and 36th month.

The results were also observed in all the other symptoms related to vaginal atrophy, such as infections, incontinence and abnormal sensitivity. Reduction of infections and incontinence is really important in order to reduce the indirect costs.

This case series confirmed our preliminary data previously published. Hence, MFAT seems a viable solution for the treatment of vaginal atrophy in order to reverse the symptom with a treatment performed only once. Furthermore, it represents not a symptomatic treatment but a disease-modifying therapy, as it seems to restore the normal physiologic status of urogenital mucosa and submucosa.

The main bias of the study is related to the design as it is only a case series of selected patients. Furthermore, another bias could also be related to the fact that our patients were relatively young.

These results have to be confirmed by randomized controlled trials with a control group and it will be important to evaluate the responsiveness of patients already treated with HRT. It has to be better understood how to select patients who will be most responsive, and which are the criteria that could be indicative of a good or poor response.

Nevertheless, to our knowledge this case series represents the first comprehensive analysis of a possible new treatment for a clinical problem that affects several millions of patients. If our results will be confirmed, we may have the opportunity to provide the first effective treatment for genitourinary atrophy and not only to modulate the symptoms.

Conclusions

This is the first large long-term (three years) case series of safety and effectiveness of micro-fractured autologous fat tissue local injection for the treatment of genitourinary atrophy. Our results have shown that this treatment is able not only to control symptoms associated with this disease but also to reduce the atrophy and its morphological changes at least up to 3 years.

Conflict of Interest

Giovanni Casarotti did not have to declare any conflict of interest related to the article; Carlo Tremolada is founder and inventor of Lipogems.

Acknowledgements

We acknowledge Prof. Mark Slevin for his contribution in the revision of the text.

Author Contribution

CG collected data, analyzed data and supervised the article, TC collected data, analyzed data, wrote and supervised the article.

References

- 1) SEMMENS JP, WAGNER G. Estrogen deprivation and vaginal function in postmenopausal women. *JAMA* 1982; 248: 445-448.
- 2) PANDIT L, OUSLANDER JG. Postmenopausal vaginal atrophy and atrophic vaginitis. *Am J Med Sci* 1997; 314: 228-231.

- 3) PABICH WL, FIHN SD, STAMM WE, SCHOLDS D, BOYKO EJ, GUPTA K. Prevalence and determinants of vaginal flora alterations in postmenopausal women. *J Infect Dis* 2003; 188: 1054-1058.
- 4) TAN O, BRADSHAW K, CARR BR. Management of vulvovaginal atrophy-related sexual dysfunction in postmenopausal women: an up-to-date review. *Menopause* 2012; 19: 109-117.
- 5) NAPPI RE, NILAND EA. Women's perception of sexuality around the menopause: outcomes of a European telephone survey. *Eur J Obstet Gynecol Reprod Biol* 2008; 137: 10-16.
- 6) BACHMANN GA, NEVADUNSKY NS. Diagnosis and treatment of atrophic vaginitis. *American Family Physician* 2000; 61: 3090-3096.
- 7) MANSON JE, ARAGAKI AK, ROSSOUW JE, ANDERSON GL, PRENTICE RL, LACROIX AZ, CHLEBOWSKI RT, HOWARD BV, THOMSON CA, MARGOLIS KL, LEWIS CE, STEFANICK ML, JACKSON RD, JOHNSON KC, MARTIN LW, SHUMAKER SA, ESPELAND MA, WACTAWSKI-WENDE J; WHI investigators. Menopausal hormone therapy and long-term all-cause and cause-specific mortality: The Women's Health Initiative randomized trials. *JAMA* 2017; 318: 927-938.
- 8) ROBINSON D, CARDOZO L. Urogenital effects of hormone therapy. *Best Pract Res Clin Endocrinol Metab* 2003; 17: 91-104.
- 9) ASSAF AR, BUSHMAKIN AG, JOYCE N, LOUIE MJ, FLORES M, MOFFATT M. The relative burden of menopausal and postmenopausal symptoms versus other major conditions: a retrospective analysis of the Medical Expenditure Panel Survey data. *Am Health Drug Benefits* 2017; 10: 311-321.
- 10) GANDHI J, CHEN A, DAGUR G, SUH Y, SMITH N, CALI B, KHAN SA. Genitourinary syndrome of menopause: an overview of clinical manifestations, pathophysiology, etiology, evaluation, and management. *Am J Obstet Gynecol* 2016; 215: 704-711.
- 11) SCHULMAN IH, BALKAN W, HARE JM. Mesenchymal stem cell therapy for aging frailty. *Front Nutr* 2018; 5: 108.
- 12) VEZZANI B, GOMEZ-SALAZAR M, CASAMITJANA J, TREMOLADA C, PÉAULT B. Human adipose tissue micro-fragmentation for cell phenotyping and secretome characterization. *J Vis Exp* 2019; 152: doi: 10.3791/60117.
- 13) VEZZANI B, SHAW I, LESME H, YONG L, KHAN N, TREMOLADA C, PÉAULT B. Higher pericyte content and secretory activity of microfragmented human adipose tissue compared to enzymatically derived stromal vascular fraction. *Stem Cells Transl Med* 2018; 7: 876-88.
- 14) TREMOLADA C, COLOMBO V, VENTURA C. Adipose tissue and mesenchymal stem cells: state of the art and Lipogems® technology development. *Curr Stem Cell Rep* 2016; 2: 304-312.
- 15) KASAP B, KASAP Đ, VATANSEVER S, KENDIRCI R, YILMAZ O, ÇALIŞIR M, EDGÜNLÜ T, AKIN MN. Effects of adipose and bone marrow-derived mesenchymal stem cells on vaginal atrophy in a rat menopause model. *Gene* 2019; 711: 143937.
- 16) CASAROTTI GA, CHIODERA P, TREMOLADA C. Menopause: new frontiers in the treatment of urogenital atrophy. *Eur Rev Med Pharmacol Sci* 2018; 22: 567-574.
- 17) NAVA S, SORDI V, PASCUCCI L, TREMOLADA C, CIUSANI E, ZEIRA O, CADEI M, SOLDATI G, PESSINA A, PARATI E, SLEVIN M, ALESSANDRI G. Long-lasting anti-inflammatory activity of human microfragmented adipose tissue. *Stem Cells Int* 2019; 2019: 5901479.
- 18) HERSANT B, SIDAHMED-MEZI M, BELKACEMI Y, DARMON F, BASTUJI-GARIN S, WERKOFF G, BOSCH R, NIDDAM J, HERMEZIU O, LA PADULA S, MENINGAUD JP. Efficacy of injecting platelet concentrate combined with hyaluronic acid for the treatment of vulvovaginal atrophy in postmenopausal women with history of breast cancer: a phase 2 pilot study. *Menopause* 2018; 25: 1124-1130.
- 19) CESERANI V, FERRI A, BERENZI A, BENETTI A, CIUSANI E, PASCUCCI L, BAZZUCCHI C, COCCÉ V, BONOMI A, PESSINA A, GHEZZI E, ZEIRA O, CECCARELLI P, VERSARI S, TREMOLADA C, ALESSANDRI G. Angiogenic and anti-inflammatory properties of micro-fragmented fat tissue and its derived mesenchymal stromal cells. *Vasc Cell* 2016; 8: 3.
- 20) ONESTI MG, CARELLA S, CECCARELLI S, MARCHESE C, SCUDERI N. The use of human adipose-derived stem cells in the treatment of physiological and pathological vulvar dystrophies. *Stem Cells Int* 2016; 2561461.