


Arthroscopic Rotator Cuff Repair Augmentation With Autologous Microfragmented Lipoaspirate Tissue Is Safe and Effectively Improves Short-term Clinical and Functional Results

A Prospective Randomized Controlled Trial With 24-Month Follow-up

Pietro S. Randelli,^{*†‡§} MD, Davide Cucchi,^{†||} MD , Chiara Fossati,^{†‡} PhD, Linda Boerci,[¶] MD, Elisabetta Nocerino,[#] MD, Federico Ambrogi,^{**} PhD, and Alessandra Menon,^{†‡††} PhD
Investigation performed at IRCCS Policlinico San Donato, San Donato Milanese, Italy & U.O.C. 1° Clinica Ortopedica, ASST Gaetano Pini-CTO, Milan, Italy

Background: Autologous microfragmented lipoaspirate tissue has been recently introduced in orthopaedics as an easily available source of nonexpanded adipose-derived mesenchymal stem cells. Autologous microfragmented lipoaspirate tissue is expected to create a suitable microenvironment for tendon repair and regeneration. Rotator cuff tears show a high incidence of rerupture and represent an ideal target for nonexpanded mesenchymal stem cells.

Purpose: To evaluate the safety and efficacy of autologous lipoaspirate tissue in arthroscopic rotator cuff repair.

Study Design: Randomized controlled trial; Level of evidence, 2.

Methods: Consecutive patients referring to the investigation center for surgical treatment of magnetic resonance imaging-confirmed degenerative posterosuperior rotator cuff tears were assessed for eligibility. Those who were included were randomized to receive a single-row arthroscopic rotator cuff repair, followed by intraoperative injection of autologous microfragmented adipose tissue processed with an enzyme-free technology (treatment group) or not (control group). Clinical follow-up was conducted at 3, 6, 12, 18, and 24 months; at 18 months after surgery, magnetic resonance imaging of the operated shoulder was obtained to assess tendon integrity and rerupture rate.

Results: An overall 177 patients were screened, and 44 (22 per group) completed the 24-month follow-up. A statistically significant difference in favor of the treatment group in terms of Constant-Murley score emerged at the primary endpoint at 6-month follow-up (mean \pm SD; control group, 76.66 ± 10.77 points; treatment group, 82.78 ± 7.00 points; $P = .0050$). No significant differences in clinical outcome measures were encountered at any of the other follow-up points. No significant differences emerged between the groups in terms of rerupture rate, complication rate, and number of adverse events.

Conclusion: This prospective randomized controlled trial demonstrated that the intraoperative injection of autologous microfragmented adipose tissue is safe and effective in improving short-term clinical and functional results after single-row arthroscopic rotator cuff repair.

Registration: NCT02783352 (ClinicalTrials.gov identifier).

Keywords: arthroscopic rotator cuff repair; biological augmentation; lipoaspirate; adipose tissue; adipose stem cells; mesenchymal stem cells; randomized controlled trial; magnetic resonance imaging; clinical results; rerupture

techniques and biological solutions to enhance tendon healing are being developed at a fast pace, as shown by the dramatic increase in the number of articles published per year.²⁵ Biological solutions to enhance rotator cuff healing include growth factors and platelet-rich plasma, as well as mesenchymal stem cells (MSCs) and their derivatives.³⁴ MSCs are believed to enhance tissue healing mainly through stimulation of local cells via paracrine mechanisms and anti-inflammatory and/or immunomodulatory activity, thus creating a suitable microenvironment for tissue repair.^{2,12,22,26,27,36,37,39} Autologous microfragmented lipoaspirate tissue has been recently introduced in orthopaedics as an easily available source of adipose-derived MSCs (ADSCs) to support and accelerate tissue regeneration. Lipoaspirates contain human ADSCs and produce growth factors, such as platelet-derived growth factor, fibroblast growth factor, transforming growth factor beta, and vascular endothelial growth factor, which play important regulatory roles in cellular functions, including adhesion, chemotaxis, proliferation, migration, matrix synthesis, differentiation, and angiogenesis.^{33,43} Herewith, autologous microfragmented lipoaspirate tissue is expected to optimize the microenvironment for tendon regeneration. Among many approaches, devices relying on nonenzymatic methods and avoiding the use of additives and other additional manipulations (eg, centrifugation) allow one to harvest, process, and obtain autologous microfragmented lipoaspirate tissue directly in the operative theater under sterile conditions. This permits immediate use in the same surgical intervention without delays owing to the difficulty of an *ex vivo* cell expansion and the complexity of the current good manufacturing practice requirements for preparing cells for therapeutic use.³³

Although several animal studies have been published showing promising results for the use of ADSCs in enhancing the healing of rotator cuff tears,²⁸ minimal evidence describing augmentation of rotator cuff treatment with lipoaspirate tissue or ADSCs is currently available.^{10,17-19,44} To date, no prospective study has evaluated the use of such therapeutic approaches *in vivo* on rotator cuff repair. The aim of this prospective randomized controlled single-blind clinical trial was to evaluate the safety and efficacy of autologous microfragmented lipoaspirate tissue in arthroscopic rotator cuff repair.

METHODS

Study Design

The primary goal of this study was to test the following hypothesis: an intraoperative injection of autologous microfragmented adipose tissue processed with an enzyme-free technology could improve the clinical outcomes of single-row arthroscopic rotator cuff repair in terms of points in the Constant-Murley score (CMS) collected 6 months after surgery.

The CONSORT (Consolidated Standards of Reporting Trials) statement guidelines were followed for result presentation. A flow diagram according to the CONSORT guidelines illustrates the grouping and flow of patients in our clinical study (Figure 1).

The study protocol was approved by the regional ethical committee (Ospedale San Raffaele-IRCCS, 148/INT/2015, January 13, 2016; amendment 1, March 9, 2017; Fondazione IRCCS Ca' Granda Ospedale Maggiore Policlinico-Milano Area 2, 132/2017, February 27, 2017) and registered at ClinicalTrials.gov (NCT02783352; March 9, 2016).

All investigations were performed at the IRCCS Policlinico San Donato, San Donato Milanese, Italy, and the ASST Centro Specialistico Ortopedico Traumatologico Gaetano Pini-CTO, Milan, Italy.

Randomization Procedures, Enrollment, Allocation, and Preoperative Evaluations

Block randomization was performed to prepare a list through a computer-generated simple randomization system and allocate patients at a 1:1 ratio to either of the 2 study groups. An independent investigator (A.M.) not involved in the clinical evaluation or surgical treatment of patients prepared and sealed progressively numbered opaque envelopes containing indications on the assigned groups.

Consecutive patients referring to the investigation center for surgical treatment of magnetic resonance imaging (MRI)-confirmed degenerative posterosuperior rotator cuff tears were assessed for eligibility and enrolled by 3 investigators not involved in the surgical procedures (D.C., C.F., L.B.) between February 2016 and April 2018, according to the inclusion and exclusion criteria listed in Table 1. All

*Address correspondence to Pietro S. Randelli, MD, U.O.C. 1° Clinica Ortopedica, ASST Gaetano Pini-CTO, Piazza Cardinal Ferrari 1, 20122 Milan, Italy (email: pietro.randelli@unimi.it).

[†]Laboratory of Applied Biomechanics, Department of Biomedical Sciences for Health, Università degli Studi di Milano, Milan, Italy.

[‡]U.O.C. 1° Clinica Ortopedica, ASST Gaetano Pini-CTO, Milan, Italy.

[§]REsearch Center for Adult and Pediatric Rheumatic Diseases, Department of Biomedical Sciences for Health, Università degli Studi di Milano, Milan, Italy.

^{||}Department of Orthopaedics and Trauma Surgery, Universitätsklinikum Bonn, Bonn, Germany.

[¶]Orthopedic Department, San Gerardo Hospital, University of Milano-Bicocca, Milan, Italy.

[#]Department of Diagnostic and Interventional Radiology, IRCCS Policlinico San Donato, San Donato Milanese, Italy.

^{**}Department of Clinical Sciences and Community Health, Laboratory of Medical Statistics, Biometry and Epidemiology "G.A. Maccaro," Università degli Studi di Milano, Milan, Italy.

^{††}Department of Clinical Sciences and Community Health, Università degli Studi di Milano, Milan, Italy.

P.S.R. and D.C. contributed equally to this work.

Submitted June 29, 2021; accepted January 3, 2022.

One or more of the authors has declared the following potential conflict of interest or source of funding: P.S.R. has received consulting fees from DePuy (J&J), Arthrex, Microport, and Medacta. AOSSM checks author disclosures against the Open Payments Database (OPD). AOSSM has not conducted an independent investigation on the OPD and disclaims any liability or responsibility relating thereto.

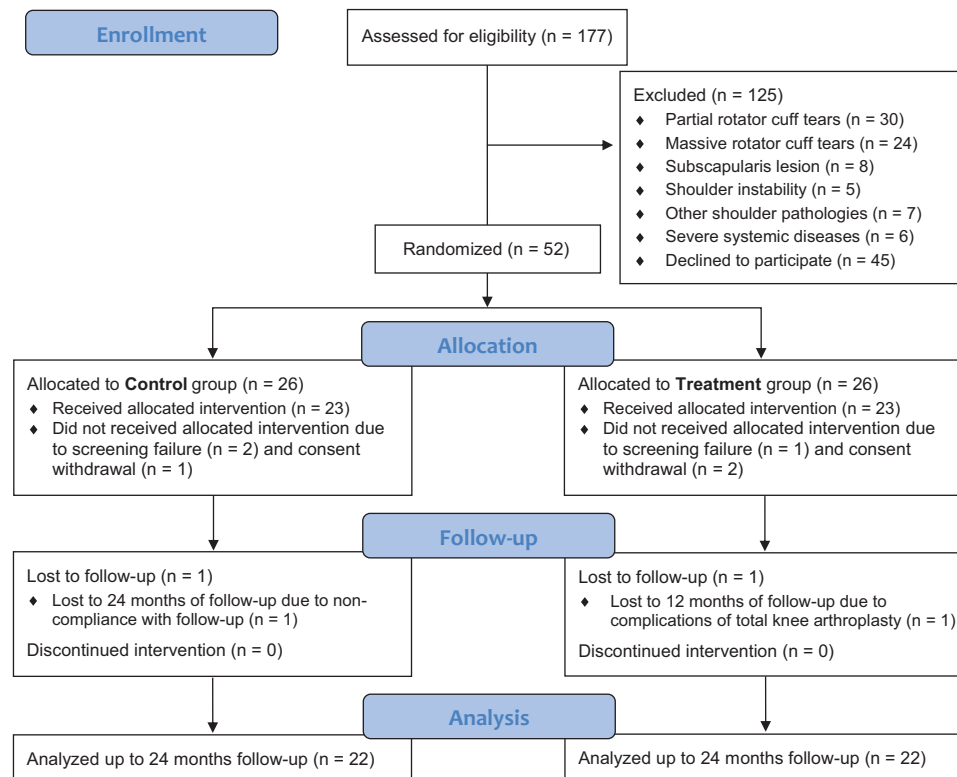


Figure 1. Flow diagram of the study utilizing the CONSORT (Consolidated Standards of Reporting Trials) statement guidelines.

enrolled patients underwent clinical examinations and preoperative blood tests and were asked to complete the American Shoulder and Elbow Surgeons (ASES) questionnaire and Simple Shoulder Test (SST) as well as a Visual Analog Scale (VAS) for pain. During the preoperative clinical evaluation, the CMS was collected, and isometric strength was measured in shoulder forward flexion, abduction, and external rotation. All measures were performed in triplicate with a dynamometer (Kern HCB; Kern & Sohn GmbH).

After enrollment and clinical examination, patients were randomized to the control group (single-row arthroscopic rotator cuff repair without adipose tissue injection) or the treatment group (single-row arthroscopic rotator cuff repair followed by intraoperative injection of autologous microfragmented adipose tissue processed with an enzyme-free technology).

All patients randomized to the treatment group underwent an additional ultrasound investigation of the abdomen to exclude asymptomatic abdominal hernias, which could represent a contraindication to abdominal adipose tissue harvest.

Surgical Procedures

All surgical procedures were performed under sedation and interscalene brachial plexus block by a single surgeon with extensive experience in shoulder arthroscopy who was not involved in the enrollment procedures or the collection of the postoperative outcome measures (P.S.R.).

The patient was positioned in the lateral decubitus position, with a traction device keeping the upper limb at approximately 30° of flexion and 30° of abduction. Diagnostic arthroscopy was performed from standard posterior, midglenoid, and lateral portals. The size of the tear was measured in its anteroposterior and mediolateral maximal extension with a graduated probe and classified according to the Southern California Orthopaedic Institute,³⁸ and the shape of the tear was classified as crescent, U, L, and inverted L.⁸ If insertional or intra-articular degeneration of the long head of the biceps was encountered, a tenotomy without tenodesis was performed.

The most lateral edges of the lesions underwent debridement and standard single-row repair with titanium suture anchors (Corkscrew, Arthrex; Super Revo FT and ThRevo FT Suture Anchors; ConMed), using a combination of margin convergence techniques and direct lateral repair depending on tear shape and mobility; if necessary, interval slides were performed to mobilize retracted tendons. Acromioplasty was performed with the Sampson cutting block technique²⁹ in patients with type 2 or 3 acromial morphology according to the Bigliani classification.⁵

Autologous Microfragmented Adipose Tissue Harvest and Preparation: Treatment Group

Patients randomized to the treatment group received an additional intraoperative injection of autologous microfragmented adipose tissue processed with an enzyme-free

TABLE 1
Eligibility Criteria^a

Inclusion criteria	<p>Age >18 years</p> <p>Full-thickness supraspinatus and infraspinatus tendon tears (C1, C2, and C3 according to the SCOI classification³⁸)</p> <p>Indication for arthroscopic rotator cuff repair</p> <p>Informed consent to participate in the study</p> <p>Informed consent to participate for the duration of the study</p>
Exclusion criteria	<p>Partial rotator cuff tendon tears (A1, A2, A3, B1, B2, and B3 according to the SCOI classification³⁸)</p> <p>Massive rotator cuff tear (C4 according to the SCOI classification)</p> <p>Subscapularis tendon tear (grade III, IV, or IV according to Lafosse classification²⁴)</p> <p>Associated anterior, posterior, or multidirectional shoulder instability</p> <p>Indication for repair of a SLAP lesion of the biceps anchor</p> <p>Grade III or IV muscle atrophy of the supraspinatus and infraspinatus tendons (according to Goutallier or Fuchs classification^{11,13})</p> <p>Intra-articular hyaluronic acid or corticosteroid infiltration within 3 mo from the planned surgical procedure</p> <p>Medical comorbidities contraindicating arthroscopic shoulder surgery</p> <p>Local (shoulder, abdominal region, gluteal region) or systemic infection, osteomyelitis, or sepsis</p> <p>Diabetes mellitus, untreated thyroid disease, chronic kidney disease, rheumatoid arthritis</p> <p>Immunodeficiency</p> <p>Chronic disorders involving coagulation, platelet aggregation, or severe coagulopathy</p> <p>Severe cardiovascular disease</p> <p>Stroke or acute cardiovascular event within 6 mo from the planned surgical procedure</p> <p>Weight loss for any cause >30 kg in 12 mo or >10 kg in 12 mo without a cause</p> <p>Eating disorders or body dysmorphic disorder</p> <p>Varices, phlebitis, or scars next to the planned adipose tissue harvesting site</p> <p>Alcohol/drug addiction or psychiatric disease compromising compliance with postoperative protocols</p> <p>Pregnancy or breastfeeding women</p> <p>Informed consent not accepted</p>

^aSCOI, Southern California Orthopaedic Institute; SLAP, superior labrum anterior and posterior.

technology. The Lipogems device (PCT/IB2011/052204) was used to harvest, process, and inject the autologous tissue under sterile conditions according to the manufacturer's instruction⁴ during the same surgical procedure as the rotator cuff repair.

Adipose tissue was harvested either from the abdomen (with the patient placed in a supine position, switching to lateral decubitus for the shoulder arthroscopy after adipose tissue harvest), or from the gluteal region (with the patient directly placed in a lateral decubitus position for both adipose tissue harvest and shoulder arthroscopy), depending on the preoperative ultrasound evaluation of the abdomen, the macroscopic availability of adipose tissue, and the patient's preference. This procedure was performed by a plastic surgeon with dedicated training for liposuction procedures before final patient positioning and draping for shoulder arthroscopy.

After skin preparation and dedicated draping, a solution of 50-mL saline 0.9%, 5-mL mepivacaine 1%, and 5-mL epinephrine 1% was infiltrated into the subcutaneous tissue using a 19G needle. Afterward, a disposable 19-cm blunt cannula with 5 oval holes connected to a 10-mL Luer-Lok syringe (Becton Dickinson) was used to aspirate a volume of 100 to 150 mL of adipose tissue (lipoaspirate).

This lipoaspirate was processed in the dedicated adipose tissue-processing device, rigorously avoiding the presence of air, first by pushing it through a cluster reduction filter and then by mechanical emulsification through shaking the lipoaspirate in the completely closed system with 5

stainless-steel beads. This separated and washed away oil and blood using the gravity counterflow of saline solution. Adipocyte clusters collected at the top of the adipose tissue-processing device underwent a second adipose cluster reduction by being passed through a size reduction filter. The final product (approximately 60-100 mL) was then collected into 10-mL syringes for subsequent use (Figure 2).

At the end of the arthroscopic procedure, fluid was carefully aspirated via the anterior outflow cannula, and autologous microfragmented adipose tissue was injected in dry arthroscopy conditions from the lateral portal while maintaining a subacromial view from the posterior portal (Figure 3).

Rehabilitation Protocol

Postoperative protocols were identical for both groups. Patients were discharged the day after surgery wearing a sling (Ultrasling II; DonJoy), and they were instructed to wear it day and night for 28 days; they were allowed to remove it to eat and to perform personal hygiene, early self-assisted light passive range of motion (ROM) exercises, and mobilization of the elbow and scapulothoracic joint. From the 29th day, patients began formal passive rehabilitation assisted by a dedicated physical therapist to recover full ROM of the shoulder joint, and they started active training once a satisfactory passive ROM was reached. From the end of the second month, the main focus of physical therapy was to regain full muscle strength.

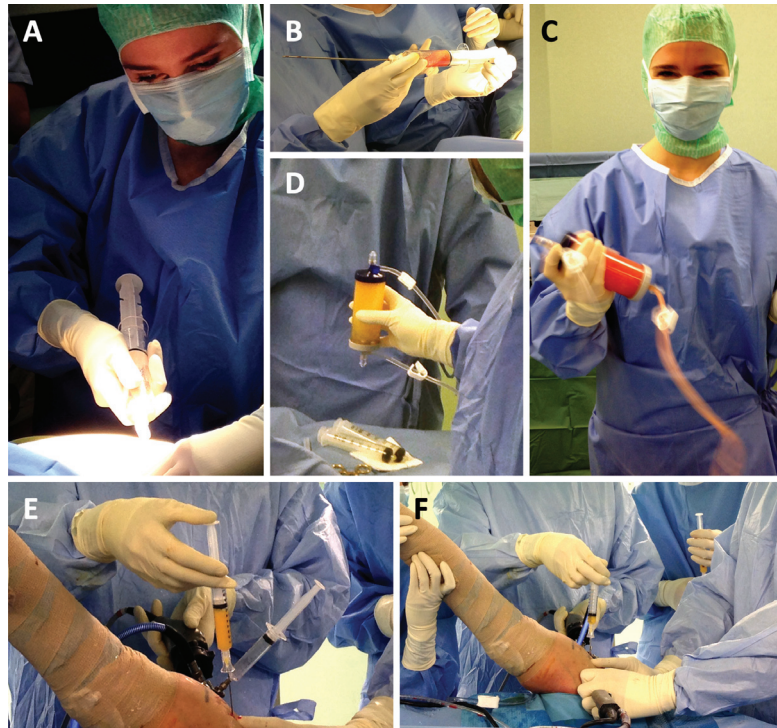


Figure 2. Adipose tissue harvest, preparation, and intraoperative injection with the Lipogems device. (A) Liposuction is performed to (B) obtain a lipoaspirate, which is then (C) mechanically emulsified through shaking to (D) separate and wash away oil and blood using a gravity counterflow. The final Lipogems product is then (E) injected at the repaired rotator cuff site from the lateral portal, after fluid aspiration from the anterior midglenoid portal and while (F) maintaining a subacromial view from the posterior portal.

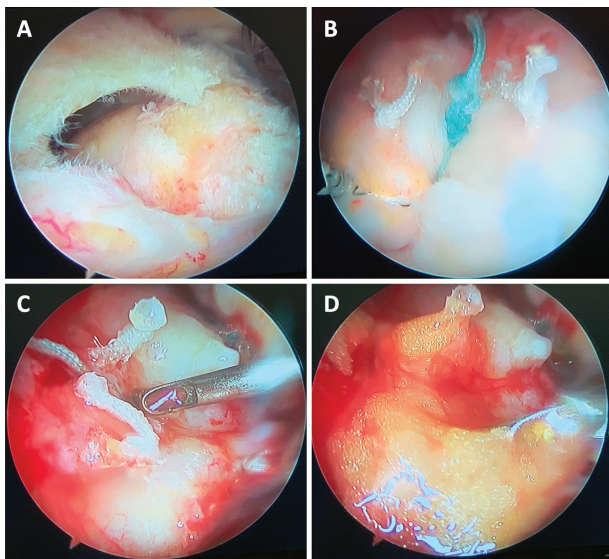


Figure 3. Intraoperative view of an arthroscopic procedure of single-row rotator cuff repair, followed by intraoperative injection of autologous microfragmented adipose tissue (right shoulder, posterior view). The (A) rotator cuff lesion is arthroscopically repaired with (B) a standard single-row construct. At the end of the procedure, in a dry condition, autologous microfragmented adipose tissue is injected (C) from the lateral portal to well cover (D) the repaired rotator cuff.

Patients undergoing abdominal lipoaspiration were discharged wearing an abdominal compression girdle for 3 weeks to prevent the development of painful subcutaneous hematomas.

Postoperative Evaluations

All patients were asked to complete a daily form documenting the perceived level of pain (VAS) at 6 PM and the daily intake of pain medications for the first 4 weeks after surgery. One month after surgery, patients were additionally asked to complete the ASES questionnaire and SST. At 3, 6, 12, 18, and 24 months of follow-up, all enrolled patients were asked to complete the ASES questionnaire, SST, and VAS, and they underwent a clinical examination, including the CMS and measurement of isometric strength in shoulder forward flexion, abduction, and external rotation. All strength measures were performed in triplicate with a dynamometer (Kern HCB; Kern & Sohn GmbH).

Eighteen months after surgery, MRI of the operated shoulder was obtained to assess tendon integrity and calculate rerupture rate according to the classification proposed by Sugaya et al⁴⁰ (types IV and V defined as retears). Atrophy of the supraspinatus muscle belly was evaluated according to Warner et al,⁴⁵ and fatty degeneration was classified according to Fuchs et al.¹¹ All MRI evaluations were performed by a dedicated musculoskeletal radiologist (E.N.) blinded to the patients' allocation.

TABLE 2
Patient Characteristics at Baseline^a

	Overall (n = 46)	Control (n = 23)	Treatment (n = 23)
Age at follow-up, y			
Mean ± SD	58.91 ± 7.04	59.43 ± 6.29	58.39 ± 7.83
Median [Q1-Q3]	58.50 [54.75-63.50]	59.00 [56.00-62.00]	57.00 [54.00-65.00]
Body mass index			
Mean ± SD	25.76 ± 4.74	25.23 ± 4.76	26.29 ± 4.77
Median [Q1-Q3]	25.06 [22.15-28.36]	24.62 [21.78-26.56]	26.22 [22.35-29.05]
Sex			
Female	27 (58.70)	15 (65.22)	12 (52.17)
Male	19 (41.30)	8 (34.78)	11 (47.83)
Treated side			
Left	9 (19.57)	4 (17.39)	5 (21.74)
Right	37 (80.43)	19 (82.61)	18 (78.26)
Dominant side			
Left	7 (15.22)	5 (21.74)	2 (8.70)
Right	39 (84.78)	18 (78.26)	21 (91.30)
Smoking ^b			
Former/current smoker	5 (11.63)	4 (18.18)	1 (4.76)
Nonsmoker	38 (88.37)	18 (81.82)	20 (95.24)
Allergies ^c			
Yes	16 (35.56)	6 (27.27)	10 (43.48)
No	29 (64.44)	16 (72.73)	13 (56.52)

^aData are presented as No. (%) unless noted otherwise. Q1, first quartile; Q3, third quartile.

^bData were missing for 3 patients (1 in control and 2 in treatment).

^cData were missing for 1 patient (control).

Blinding

Blinding of patients to the allocated intervention was not performed for obvious technical and ethical reasons. Randomization procedures and statistical analyses were performed by an examiner not involved in the clinical evaluation or surgical treatment of patients. All clinical evaluations were performed by independent examiners (D.C., C.F., L.B.) not involved in the surgical procedures but not blinded to the patients' allocation. The dedicated musculoskeletal radiologist evaluating MRI investigations was blinded to the patients' allocation.

Statistical Analysis

Sample Size Calculation. A power analysis was performed per the literature review. It is evident that several months after rotator cuff tear repair, there is a 30% decrease in strength in the operated shoulder (about 7 points less in terms of CMS). Therefore, the primary outcome measure was the mean score of the validated CMS. The alternative hypothesis was that the CMS would be 7 points higher in the treatment group (where patients underwent arthroscopic repair and injection of microfragmented lipoaspirate product) in comparison with the control group (where patients underwent only arthroscopic rotator cuff repair).

The sample size calculation was carried out per the literature data and a conservative estimate of the SD of 8 points. With these parameters 44 participants were needed (22 in

each group) to detect a difference of 7 points in terms of CMS between the treatment and control groups, setting a type 1 error (α) of 5% and a power of 80%. We anticipated a high level of dropout for personal reasons and other conditions that would prevent participation for the entire study; thus, with an expected dropout rate of 15%, the sample size was set at 52 participants (26 in each group).

Results Analysis. Statistical analysis was performed using R Statistical Software (Version 4.0.0; R Foundation for Statistical Computing) and Prism software (Version 6.0; GraphPad Software Inc) by statisticians (A.M., F.A.) blinded to the control and intervention groups in the data set. Continuous variables were expressed as mean and standard deviation or median and first and third quartiles, as appropriate.

The within-group differences from baseline to different follow-ups for continuous variables were evaluated with the paired *t* test or Wilcoxon matched-pairs signed-rank test, according to the characteristics of the data distribution evaluated using the Shapiro-Wilk normality test. Analysis of covariance was used to compare response means between the groups over follow-ups. Homogeneity of regression slopes was evaluated by the interaction between trial arm and baseline score measurements. Normality of residuals and homogeneity of the variances were evaluated using the Shapiro-Wilk and Levene tests. Where appropriate, a nonparametric analysis of covariance was applied (Version 2.2-5.6; R package *sm*: nonparametric smoothing methods).⁴⁷

Categorical variables are expressed in numbers of cases or frequencies; their differences were tested with the chi-

TABLE 3
Intraoperative Data for the Control and Treatment Groups^a

	Overall	Control	Treatment
Lesion type (SCOI classification)			
C1	19 (41.30)	11 (47.83)	8 (34.78)
C2	17 (36.96)	7 (30.43)	10 (43.48)
C3	10 (21.74)	5 (21.74)	5 (21.74)
Tear shape			
Crescent	28 (65.12)	12 (60)	16 (69.57)
U-shaped	4 (9.30)	3 (15)	1 (4.35)
L-shaped	7 (16.28)	3 (15)	4 (17.39)
Inverted L	4 (9.30)	2 (10)	2 (8.69)
Tear extension, mm			
Anteroposterior			
Mean \pm SD	15.05 \pm 7.53	13.57 \pm 8.16	16.39 \pm 6.81
Median [Q1-Q3]	12.00 [10.00-20.00]	11.00 [9.00-17.50]	16.00 [10.00-21.00]
Mediolateral			
Mean \pm SD	16.50 \pm 11.22	16.10 \pm 10.43	16.87 \pm 12.13
Median [Q1-Q3]	12.00 [10.00-20.00]	10.00 [9.50-21.50]	12.00 [10.00-20.00]
No. of anchors			
Mean \pm SD	1.31 \pm 0.47	1.29 \pm 0.46	1.33 \pm 0.48
Median [Q1-Q3]	1.00 [1.00-2.00]	1.00 [1.00-2.00]	1.00 [1.00-2.00]
No. of sutures			
Mean \pm SD	3.41 \pm 1.38	3.38 \pm 1.40	3.42 \pm 1.40
Median [Q1-Q3]	3.00 [2.00-4.00]	3.00 [2.00-4.50]	3.00 [2.50-4.00]
Side-to-side repair			
Yes	3 (7.14)	2 (8.70)	1 (4.35)
No	39 (92.86)	21 (91.30)	22 (95.65)
Interval slide			
Yes	5 (11.63)	2 (8.70)	3 (13.04)
No	38 (88.37)	21 (91.30)	20 (86.96)
Acromion type according to Bigliani et al ⁵			
1	12 (27.91)	5 (22.73)	7 (33.33)
2	24 (55.81)	15 (68.18)	9 (42.86)
3	7 (16.28)	2 (9.09)	5 (23.81)

^aData are presented as No. (%) unless noted otherwise. Q1, first quartile; Q3, third quartile; SCOI, Southern California Orthopaedic Institute.

square test or Fisher exact test. For all analyses, the significance level was set at $P < .05$.

RESULTS

An overall 177 consecutive patients were screened for inclusion; 52 were enrolled and randomized; 46 received the allocated treatment; and 44 completed the 24-month follow-up period ($n = 22$ each for the control and treatment groups) (Figure 1). Time to follow-up at each study time point is reported in Appendix Table A1 (available in the online version of this article).

Characteristics of the included patients are illustrated in Table 2 and the intraoperatively collected data in Table 3. No significant differences between the groups emerged for any of the investigated demographic and intraoperative parameters.

Primary Outcome

According to analysis of covariance, a statistically significant difference in favor of the treatment group in terms

of CMS emerged at the primary endpoint at 6-month follow-up ($P = .0050$) (Table 4, Figure 4). No significant differences in terms of CMS were encountered at the secondary endpoint of 24-month follow-up or at any of the other follow-up points.

In terms of the subscales of the CMS and the number of time points considered, the daily activities subscale maintained a significant difference in favor of the treatment group at the 6-month follow-up, also after a Bonferroni correction for multiple comparisons (adjusted $P = .0296$). No significant differences emerged for the other CMS subscales or at different time points (Table 4, Figure 4; Appendix Table A2, available online).

Secondary Outcomes

Significant differences were found in terms of the ASES questionnaire, SST, and isometric strength in external rotation at 6 months of follow-up ($P = .0265$, $P = .0164$, and $P = .0077$, respectively), revealing a superiority of the treatment group (Table 5, Figures 5 and 6). After Bonferroni correction for multiple comparisons, no secondary outcomes

TABLE 4
Clinical and Functional Results of the Primary Outcome: Constant-Murley Score^a

CMS (Points): Group	Follow-up			P Value ^b		P Value ^c		P Value ^d
	Baseline	6 mo	24 mo	6 mo	24 mo	6 mo	24 mo	
Total (0-100)						.0050	.5632	.3921
Control				<.0001	<.0001			
Mean ± SD	57.33 ± 18.41	76.66 ± 10.77	84.54 ± 5.93					
Median [Q1-Q3]	52.40 [46.08-70.18]	76.28 [68.84-88.31]	83.74 [80.86-88.74]					
Treatment				<.0001	<.0001			
Mean ± SD	49.31 ± 15.41	82.78 ± 7.00	86.28 ± 5.34					
Median [Q1-Q3]	44.70 [41.94-61.16]	81.44 [79.06-87.82]	85.45 [81.41-89.19]					
Pain (0-15)						.6127	.2917	.6734
Control				<.0001	<.0001			
Mean ± SD	8.65 ± 3.63	13.74 ± 1.84	14.55 ± 0.86					
Median [Q1-Q3]	8.00 [7.00-12.00]	14.00 [13.00-15.00]	15.00 [14.00-15.00]					
Treatment				<.0001	<.0001			
Mean ± SD	7.74 ± 3.57	14.35 ± 0.83	14.59 ± 1.18					
Median [Q1-Q3]	9.00 [4.00-11.00]	15.00 [14.00-15.00]	15.00 [15.00-15.00]					
Daily activity (0-20)						.0037	.8202	.7617
Control				<.0001	<.0001			
Mean ± SD	10.50 ± 4.77	17.39 ± 2.89	19.76 ± 0.70					
Median [Q1-Q3]	10.50 [6.00-13.25]	18.00 [16.00-20.00]	20.00 [20.00-20.00]					
Treatment				<.0001	<.0001			
Mean ± SD	8.65 ± 4.47	19.57 ± 1.12	19.86 ± 0.64					
Median [Q1-Q3]	9.00 [6.00-12.00]	20.00 [20.00-20.00]	20.00 [20.00-20.00]					
Movement (0-40)						.0198	.1606	.7406
Control				.0004	<.0001			
Mean ± SD	29.74 ± 8.75	36.17 ± 3.81	39.09 ± 1.19					
Median [Q1-Q3]	34.00 [22.00-36.00]	38.00 [34.00-38.00]	40.00 [38.00-40.00]					
Treatment				<.0001	<.0001			
Mean ± SD	26.17 ± 8.40	37.83 ± 2.08	38.91 ± 1.02					
Median [Q1-Q3]	28.00 [20.00-32.00]	38.00 [38.00-38.00]	38.00 [38.00-40.00]					
Strength (0-25)						.1190	.2654	.1652
Control				.2164	.0008			
Mean ± SD	8.42 ± 6.12	9.51 ± 5.07	11.38 ± 5.02					
Median [Q1-Q3]	7.04 [3.52-11.77]	8.36 [5.17-14.08]	10.29 [7.20-15.25]					
Treatment				.0018	.0001			
Mean ± SD	6.75 ± 4.84	10.98 ± 5.81	12.84 ± 5.51					
Median [Q1-Q3]	6.34 [3.04-10.12]	9.57 [6.82-15.84]	11.99 [8.56-17.32]					

^aBonferroni-corrected *P* values are reported in the text. CMS, Constant-Murley Score; Q1, first quartile; Q3, third quartile.

^bSignificance of the within-group changes from baseline to 6- and 24-month follow-up (paired *t* test or Wilcoxon matched-pairs signed-rank test).

^cSignificance of the between-group difference at 6- and 24-month follow-up (analysis of covariance).

^dSignificance of the between-group difference over time of the main outcome measures (longitudinal data analysis).

maintained statistical significance (adjusted *P* > .05). No significant differences were found at other follow-up points (Appendix Tables A3 and A4, available online).

No differences between the groups were encountered in perioperative VAS for pain (mm) and analgesic use within the first 4 weeks (Figure 6; Appendix Tables A5 and A6, available online).

Radiological Evaluation at 18 Months

No significant differences between the groups emerged in terms of rerupture rate within 18 months after surgery; similarly, no significant differences were documented between the groups in terms of postoperative rotator cuff

tendon integrity according to the Sugaya classification, Warner grading of muscle atrophy, and Fuchs grading for supraspinatus fatty infiltration (Table 6).

Complications and Adverse Events

No significant differences between the groups were encountered in the complication rate and in the number of adverse events throughout the duration of the study (Appendix Table A7, available online). No serious adverse events related to any intervention were encountered. No adverse events related with certainty to the harvesting procedure were documented in the treatment group.

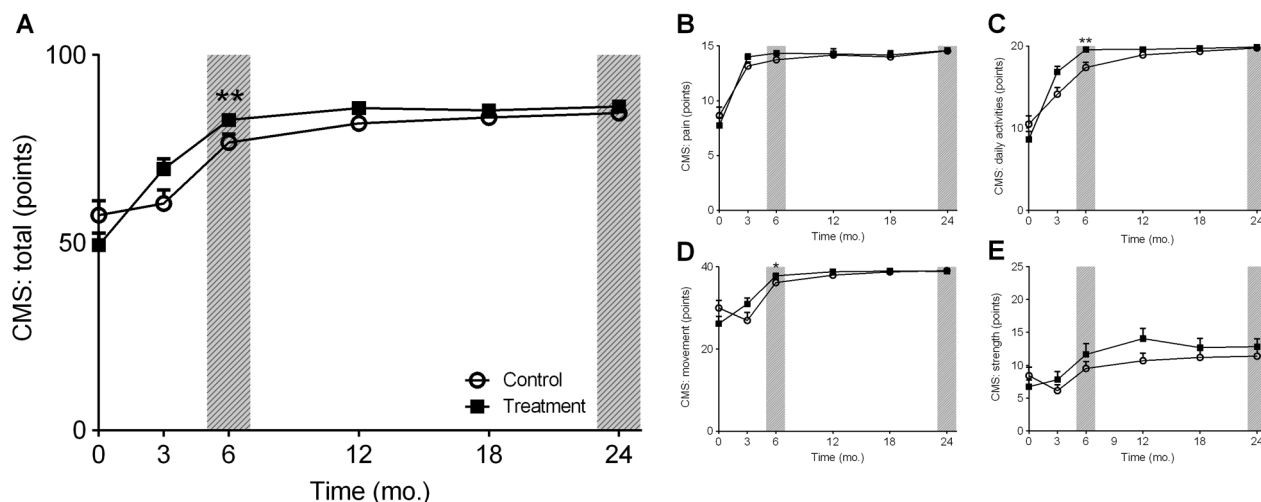


Figure 4. Comparisons of total (A) CMS and (B-E) the 4 CMS subscales between the treatment and control groups at the 3-, 6-, 12-, 18-, and 24-month postoperative follow-up. Trend curves show the treatment effect of autologous microfragmented lipoaspirate product on total CMS and CMS subscales over time as compared with the control group. Error bars indicate SEM. *P* values were calculated using analysis of covariance. Only *P* values <.05 are indicated. **P* < .05. ***P* < .01. Bonferroni-corrected *P* values are reported in the text. CMS, Constant-Murley score.

DISCUSSION

The main finding of this nonsponsored prospective randomized controlled trial was that an intraoperative injection of autologous microfragmented adipose tissue processed with an enzyme-free technology significantly improved the clinical outcomes of single-row arthroscopic rotator cuff repair in terms of total CMS 6 months after surgery. Rerupture rate and radiological quality of the repair as documented with MRI 18 months after surgery were not influenced by the treatment.

History and Evolution of Rotator Cuff Surgery Including Biological Augmentation

Surgical techniques to repair rotator cuff lesions were first proposed at the end of the 19th century and then rapidly evolved from open to arthroscopic techniques; these are still in development, with new fixation techniques and biological solutions to enhance tendon healing being proposed at a fast pace to reduce retear rates and improve functional and clinical results.³² Biological solutions to enhance rotator cuff healing include growth factors and platelet-rich plasma, as well as MSCs and their derivatives.³⁴

The term *MSC*, first used by Caplan⁶ in 1991, identifies multipotent adult stem cells, which have the potential to differentiate into various types of mesenchymal tissues and are characterized by a definite subset of surface markers, behavior in culture, and differentiating abilities.^{9,16,21} Later research suggested that, rather than directly contributing to tissue regeneration through differentiation, these cells home to sites of inflammation or tissue injury and secrete bioactive, immunomodulatory, and

trophic agents, which led to the alternative term *medicinal signalling cells*.⁷

The majority of MSCs used for orthopaedic applications are obtained from bone marrow tissue, which is relatively easy to access with substantial patient morbidity and which provide relatively high numbers of MSCs. In recent years, distinct populations of MSCs have been isolated from the rotator cuff tendons, the long head of the biceps tendon, the subacromial bursa, and the glenohumeral synovial tissue,^{20,30,41,42} suggesting the possibility of extracting these cells locally during arthroscopic shoulder procedures and eliminating the additional donor-site morbidity on the surgical site chosen for bone marrow aspiration. Nevertheless, the amount of available material for MSC extraction from shoulder periarticular tissues is limited and requires expansion in a dedicated facility before clinical use, which can be limited by regulatory restrictions concerning the advanced therapy medicinal products and the high costs of good manufacturing practice cell expansion.^{14,35} As a result, studies using tendon-derived MSCs remain limited to animal models,³¹ while clinical research has shifted focus to other sources of MSCs.

Adipose-Derived MSCs

Aside from their possibly direct participation in the repair response, MSCs are believed to enhance tissue healing mainly through stimulation of local cells via a paracrine mechanism and anti-inflammatory and/or immunomodulatory activity, thus creating a suitable microenvironment for tissue repair.^{2,12,22,26,27,36,37,39}

In this context, adipose stromal vascular fraction has been demonstrated as a potential candidate to provide an

TABLE 5
Clinical and Functional Results of the Secondary Outcomes^a

Outcome: Group	Follow-up			P Value ^b		P Value ^c		P Value ^d
	Baseline	6 mo	24 mo	6 mo	24 mo	6 mo	24 mo	
ASES (0-100 points)						.0265	.1976	.3095
Control				<.0001	<.0001			
Mean ± SD	51.01 ± 16.71	85.14 ± 14.14	94.62 ± 8.51					
Median [Q1-Q3]	48.33 [41.67-56.67]	90.00 [73.33-98.33]	99.17 [92.92-100.00]					
Treatment				<.0001	<.0001			
Mean ± SD	48.04 ± 20.28	93.99 ± 6.94	98.33 ± 4.66					
Median [Q1-Q3]	46.67 [36.67-60.00]	98.33 [90.00-100.00]	100.00 [99.58-100.00]					
SST (0-12 points)						.0164	.9733	.4522
Control				<.0001	<.0001			
Mean ± SD	6.91 ± 2.83	10.91 ± 1.47	11.91 ± 0.29					
Median [Q1-Q3]	6.00 [5.00-10.00]	12.00 [10.00-12.00]	12.00 [12.00-12.00]					
Treatment				<.0001	<.0001			
Mean ± SD	5.22 ± 2.73	11.70 ± 0.47	11.86 ± 0.35					
Median [Q1-Q3]	5.00 [4.00-7.00]	12.00 [11.00-12.00]	12.00 [12.00-12.00]					
VAS (0-100 mm)						.2617	.8152	.4425
Control				<.0001	<.0001			
Mean ± SD	43.87 ± 25.88	11.74 ± 17.23	2.46 ± 5.01					
Median [Q1-Q3]	50.00 [20.00-60.00]	5.00 [0.00-20.00]	0.00 [0.00-3.500]					
Treatment				<.0001	<.0001			
Mean ± SD	52.04 ± 22.43	5.09 ± 6.52	1.82 ± 6.08					
Median [Q1-Q3]	50.00 [40.00-70.00]	0.00 [0.00-10.00]	0.00 [0.00-0.00]					
Strength: flexion, kg						.5010	.128	.0576
Control				.2332	.0006			
Mean ± SD	3.63 ± 2.28	4.22 ± 2.24	5.17 ± 2.18					
Median [Q1-Q3]	3.60 [1.77-5.20]	3.77 [2.55-5.58]	4.69 [3.78-6.56]					
Treatment				.0001	<.0001			
Mean ± SD	2.89 ± 2.00	4.89 ± 2.93	6.20 ± 2.65					
Median [Q1-Q3]	2.82 [0.94-4.17]	3.95 [3.03-6.00]	5.82 [3.98-8.48]					
Strength: er, kg						.0077	.6601	.5747
Control				.0069	<.0001			
Mean ± SD	3.80 ± 1.85	5.11 ± 2.65	6.32 ± 2.90					
Median [Q1-Q3]	3.72 [2.50-4.73]	3.95 [3.22-6.98]	5.51 [4.18-7.46]					
Treatment				.0003	<.0001			
Mean ± SD	3.85 ± 1.92	6.06 ± 3.68	7.23 ± 2.59					
Median [Q1-Q3]	3.53 [2.50-5.47]	5.63 [3.82-6.87]	6.98 [4.91-9.27]					

^aBonferroni-corrected *P* values are reported in the text. ASES, American Shoulder and Elbow Surgeons; er, external rotation; Q1, first quartile; Q3, third quartile; SST, Simple Shoulder Test; VAS, visual analog scale.

^bSignificance of the within-group changes from baseline to 6- and 24-month follow-up (paired *t* test or Wilcoxon matched-pairs signed-rank test).

^cSignificance of the between-group difference at 6- and 24-month follow-up (analysis of covariance).

^dSignificance of the between-group difference over time of the main outcome measures (longitudinal data analysis).

acceleratory effect on the healing process of injured tendons.³ Given the abundance of adipose tissue in easily accessible regions of the human body, technologies have been developed to obtain autologous cell concentrates from adipose tissue intraoperatively without the need for cell culturing. After adipose tissue is obtained by subcutaneous liposuction and the raw lipoaspirate is washed, an intact stromal vascular niche containing cellular elements with pericyte characteristics and ADSCs can be obtained via enzymatic digestion or with nonenzymatic mechanical processes.¹

In enzymatic methods, collagenases and proteases are used to dissolve the connective tissue and isolate the stem cells. Since enzymatic digestion processes may affect cell viability, multipotency, and surface antigen expression,

nonenzymatic extraction methods have been implemented involving centrifugation or microfragmentation.^{4,15} These nonenzymatic methods lead to a lower cell yield than enzymatic methods⁴⁶ and therefore require a larger quantity of lipoaspirate, which may also affect cell viability; nevertheless, they have been demonstrated to contain ADSCs and growth factors, which both play regulatory roles in cellular differentiation, interaction, and migration as well as matrix deposition and neoangiogenesis.⁴³ As a further advantage, devices relying on nonenzymatic processing, such as the Lipogems device used in the present study, allow one to harvest, process, and obtain autologous microfragmented lipoaspirate tissue directly in the operative theater under sterile conditions. Several animal studies have been

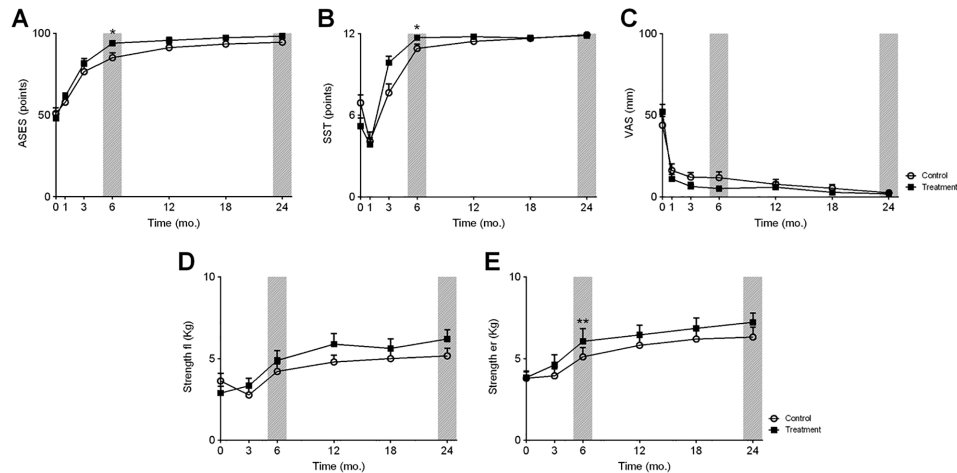


Figure 5. Comparisons of (A) American Shoulder and Elbow Surgeons (ASES) score, (B) Simple Shoulder Test (SST), (C) Visual Analog Scale (VAS), and (D) strength in flexion (fl) and (E) external rotation (er) between the treatment and control groups at the 3-, 6-, 12-, 18-, and 24-month postoperative follow-up. Trend curves show the treatment effect of autologous microfragmented lipooaspirate product on each outcome over time as compared with control group. Error bars indicate SEM. *P* values were calculated using analysis of covariance. Only *P* values <.05 are indicated. **P* <.05. ***P* <.01. Bonferroni-corrected *P* values are reported in the text.

published showing promising results for the use of ADSCs in enhancing healing of rotator cuff tears, as effectively summarized by Mocini et al.²⁸

Clinical Studies

Minimal evidence describing augmentation of rotator cuff treatment with ADSCs or lipoaspirates is currently available, and level 1 studies are completely lacking.

Hurd et al¹⁷ randomized 20 patients with symptomatic partial-thickness rotator cuff tears to receive a single injection of corticosteroid or fresh autologous adipose-derived regenerative cells, uncultured and unmodified, as obtained by liposuction and enzymatic processing no more than 2 hours before the procedure. In this pilot study with 12 months of follow-up, no severe adverse events were observed, and improved ASSES scores were documented 24 and 52 weeks after the procedure but not at other follow-up time points.

In a prospective comparative cohort study, Kim et al¹⁹ augmented rotator cuff repairs with fibrin glue loaded with ADSCs obtained by liposuction and centrifugation on the day before surgery in 35 patients. After 2 years of follow-up, no differences could be found between these patients and a matched control group in terms of VAS, ROM, CMS, and University of California Los Angeles scores. A lower retear rate was claimed after analysis of MRI investigation at 1-year follow-up.

Jo et al¹⁸ injected different doses of autologous ADSCs under ultrasound control into 18 patients with partial-thickness rotator cuff tears. ADSCs were obtained from liposuction 3 weeks before the procedure and subsequently underwent enzymatic digestion and in vitro expansion. To macroscopically evaluate the treated tendons, the authors performed diagnostic arthroscopy before and 6 months

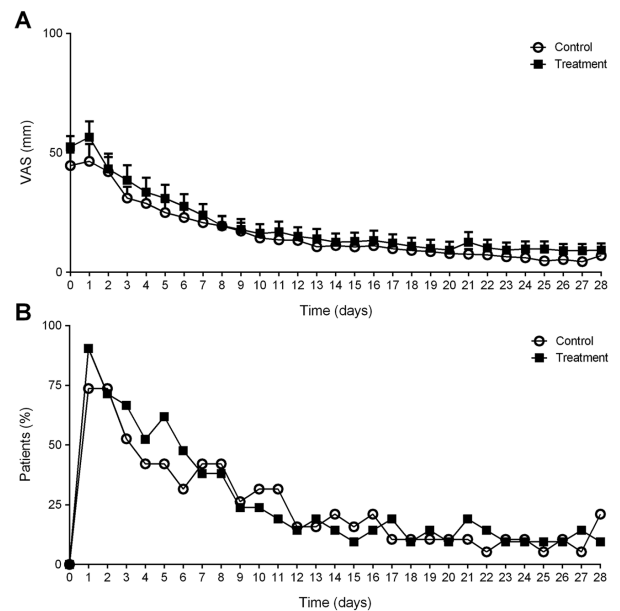


Figure 6. (A) Visual Analog Scale (VAS) for pain and (B) intake of pain medications for the treatment and control groups during the first 28 postoperative days. Trend curves show the treatment effect of autologous microfragmented lipoaspirate product during the first 28 postoperative days as compared with the control group. Error bars indicate SEM. Squares and circles indicate the percentage of patients taking pain medications.

after the procedure. Clinical results in terms of VAS, Shoulder Pain and Disability Index, and CMS score were favorable, and arthroscopic as well as MRI examination

TABLE 6
Results of the Radiological Evaluation at 18 Months of Follow-up^a

	Overall	Control	Treatment	P Value ^b
Rerupture				.6652
Yes	6 (13.33)	4 (17.39)	2 (9.09)	
No	39 (86.67)	19 (82.61)	20 (90.91)	
Sugaya type				.1062
1	12 (26.67)	8 (34.78)	4 (18.18)	
2	16 (35.56)	5 (21.74)	11 (50.00)	
3	6 (13.33)	3 (13.04)	3 (13.64)	
4	7 (15.55)	3 (13.04)	4 (18.18)	
5	4 (8.89)	4 (17.39)	0 (0)	
Warner atrophy grade				≥.999
1	13 (28.89)	7 (30.43)	6 (27.27)	
2	24 (53.33)	12 (52.17)	12 (54.55)	
3	6 (13.33)	3 (13.04)	3 (13.64)	
4	2 (4.45)	1 (4.35)	1 (4.55)	
Fuchs score				.8286
0	9 (20.45)	5 (21.74)	5 (22.73)	
1	21 (47.73)	12 (52.17)	9 (40.91)	
2	10 (22.73)	4 (17.39)	6 (27.27)	
3	1 (2.27)	0 (0)	1 (4.55)	
4	3 (6.82)	2 (8.70)	1 (4.55)	

^aData are presented as No. (%). For the radiological evaluation, data were missing for 1 patient in the treatment group owing to dropout after the 12-month follow-up, as illustrated in Figure 1.

^bSignificance of the between-group difference (chi-square or Fisher exact test).

showed a decrease in defect size in patients receiving medium and high doses of ADSCs.

This is the first study that evaluated the effects of an intraoperative injection of autologous microfragmented adipose tissue processed with an enzyme-free technology on the clinical, functional, and imaging results after single-row arthroscopic rotator cuff repair: significant improvements were documented in terms of total CMS, ASES questionnaire, SST, and strength in external rotation 6 months after surgery, suggesting an accelerated repair in the treatment group and a possibility of earlier return to work or sports. These significant differences did not persist at later follow-up time points, showing no late compromise of the initial positive results or a rebound effect. These results open novel perspectives in the enhancement of rotator cuff repair, paving the way to a possibly accelerated return to preinjury level of performance in the patients treated with autologous microfragmented adipose, which could have a particularly relevant role in sports medicine. Around the shoulder region, ADSCs have also been used to treat glenohumeral osteoarthritis (prospective case series of 25 patients with the same ADSC preparation that we used⁴⁴) and acromioclavicular joint osteoarthritis (case report, ADSCs expanded *in vitro*¹⁰), showing promising preliminary results.

Limitations

A limitation of our study was that the specific features of the lipoaspirate in terms of cells and growth factor content were not determined for each patient. Nevertheless, *ex vivo* evaluation of tissue samples could demonstrate an increase in the

proliferation rate and the vascular endothelial growth factor expression and a reduction of the catabolic and inflammatory marker expression in tendon cells derived from injured supraspinatus tendons treated with the same microfragmented adipose tissue used in the clinical application.^{33,43}

Although this study was adequately powered to show statistically and clinically relevant results based on a randomized controlled trial performed in the same field, care should be taken when extrapolating these results to other patient groups, since treatment effectiveness in terms of minimal clinically important difference may be evaluated differently in other populations.²³ Similarly, extrapolating these results to specific tear patterns should be done with caution since this study evaluated different rotator cuff tears (full-thickness tears: C1, C2, and C3 in the Southern California Orthopaedic Institute classification) without performing a subgroup analysis for each type. Furthermore, this study was powered on the primary outcome (CMS)—as a consequence, it could be underpowered for the secondary outcomes, such as the radiologic results and retear rates.

A final limitation of this randomized clinical trial is that blinding of patients to the allocated intervention was not performed for obvious technical and ethical reasons, and the evaluators were not blinded to group allocation, introducing the possibility of assessment bias.


CONCLUSION

This prospective randomized controlled trial demonstrated that the intraoperative injection of autologous microfragmented adipose tissue is safe and effective in improving

short-term clinical and functional results after single-row arthroscopic rotator cuff repair. Nevertheless, no significant differences emerged between the groups in terms of rerupture rate, complication rate, number of adverse events, and mid-term clinical outcomes.

Although still in the early stages of application, augmentation of rotator cuff repair with autologous microfragmented adipose tissue appears a suitable strategy to enhance tendon repair and regeneration.

ORCID iD

Davide Cucchi  <https://orcid.org/0000-0001-6284-7977>

REFERENCES

- Alt EU, Winnier G, Haenel A, et al. Towards a comprehensive understanding of UA-ADRCs (uncultured, autologous, fresh, unmodified, adipose derived regenerative cells, isolated at point of care) in regenerative medicine. *Cells*. 2020;9(5):1097. doi:10.3390/cells9051097
- Angeline ME, Rodeo SA. Biologics in the management of rotator cuff surgery. *Clin Sports Med*. 2012;31:645-663. doi:10.1016/j.csm.2012.07.003
- Behfar M, Sarrafzadeh-Rezaei F, Hobbenaghi R, Delirezh N, Dalir-Naghadeh B. Adipose-derived stromal vascular fraction improves tendon healing in rabbits. *Chin J Traumatol*. 2011;14(6):329-335.
- Bianchi F, Maioli M, Leonardi E, et al. A new nonenzymatic method and device to obtain a fat tissue derivative highly enriched in pericyte-like elements by mild mechanical forces from human lipoaspirates. *Cell Transplant*. 2013;22(11):2063-2077. doi:10.3727/096368912X657855
- Bigliani LU, Ticker JB, Flatow EL, Soslowsky LJ, Mow VC. The relationship of acromial architecture to rotator cuff disease. *Clin Sports Med*. 1991;10(4):823-838.
- Caplan AL. Mesenchymal stem cells. *J Orthop Res*. 1991;9:641-650. doi:10.1002/jor.1100090504.
- Caplan AL. What's in a name? *Tissue Eng Part A*. 2010;16(8):2415-2417. doi:10.1089/ten.TEA.2010.0216
- Davidson J, Burkhart SS. The geometric classification of rotator cuff tears: a system linking tear pattern to treatment and prognosis. *Arthroscopy*. 2010;26:417-424. doi:10.1016/j.arthro.2009.07.009
- Dominici M, Le Blanc K, Mueller I, et al. Minimal criteria for defining multipotent mesenchymal stromal cells: the International Society for Cellular Therapy position statement. *Cytotherapy*. 2006;8:315-317. doi:10.1080/14653240600855905
- Freitag J, Wickham J, Shah K, Tenen A. Effect of autologous adipose-derived mesenchymal stem cell therapy in the treatment of acromioclavicular joint osteoarthritis. *BMJ Case Rep*. 2019;12(2):e227865. doi:10.1136/bcr-2018-227865
- Fuchs B, Weishaupt D, Zanetti M, Hodler J, Gerber C. Fatty degeneration of the muscles of the rotator cuff: assessment by computed tomography versus magnetic resonance imaging. *J Shoulder Elbow Surg*. 1999;8(6):599-605. doi:10.1016/S1058-2746(99)90097-6
- Gneocchi M, Zhang Z, Ni A, Dzau VJ. Paracrine mechanisms in adult stem cell signaling and therapy. *Circ Res*. 2008;103(11):1204-1219. doi:10.1161/CIRCRESAHA.108.176826
- Goutallier D, Postel JM, Bernageau J, Lavau L, Voisin MC. Fatty infiltration of disrupted rotator cuff muscles. *Rev Rhum Engl Ed*. 1995;62(6):415-422.
- Guess AJ, Daneault B, Wang R, et al. Safety profile of good manufacturing practice manufactured interferon γ -primed mesenchymal stem/stromal cells for clinical trials. *Stem Cells Transl Med*. 2017;6(10):1868-1879. doi:10.1002/sctm.16-0485
- Hendijani F. Explant culture: an advantageous method for isolation of mesenchymal stem cells from human tissues. *Cell Prolif*. 2017;50(2):e12334. doi:10.1111/cpr.12334
- Horwitz EM, Le Blanc K, Dominici M, et al. Clarification of the nomenclature for MSC: the International Society for Cellular Therapy position statement. *Cytotherapy*. 2005;7:393-395. doi:10.1080/14653240500319234
- Hurd JL, Facile TR, Weiss J, et al. Safety and efficacy of treating symptomatic, partial-thickness rotator cuff tears with fresh, uncultured, unmodified, autologous adipose-derived regenerative cells (UA-ADRCs) isolated at the point of care: a prospective, randomized, controlled first-in-human pilot study. *J Orthop Surg Res*. 2020;15(1):122. doi:10.1186/s13018-020-01631-8
- Jo CH, Chai JW, Jeong EC, et al. Intratendinous injection of autologous adipose tissue-derived mesenchymal stem cells for the treatment of rotator cuff disease: a first-in-human trial. *Stem Cells*. 2018;36(9):1441-1450. doi:10.1002/stem.2855
- Kim YS, Sung CH, Chung SH, Kwak SJ, Koh YG. Does an injection of adipose-derived mesenchymal stem cells loaded in fibrin glue influence rotator cuff repair outcomes? A clinical and magnetic resonance imaging study. *Am J Sports Med*. 2017;45(9):2010-2018. doi:10.1177/0363546517702863
- Klatte-Schulz F, Pauly S, Scheibel M, et al. Influence of age on the cell biological characteristics and the stimulation potential of male human tenocyte-like cells. *Eur Cells Mater*. 2012;24:74-89. doi:10.22203/eCM.v024a06
- Krampera M, Galipeau J, Shi Y, Tarte K, Sensebe L. Immunological characterization of multipotent mesenchymal stromal cells—the International Society for Cellular Therapy (ISCT) working proposal. *Cytotherapy*. 2013;15(9):1054-1061. doi:10.1016/j.jcyt.2013.02.010
- Krasnodembskaya A, Song Y, Fang X, et al. Antibacterial effect of human mesenchymal stem cells is mediated in part from secretion of the antimicrobial peptide LL-37. *Stem Cells*. 2010;28(12):2229-2238. doi:10.1002/stem.544
- Kukkonen J, Kauko T, Vahlberg T, Joukainen A, Äärimala V. Investigating minimal clinically important difference for Constant score in patients undergoing rotator cuff surgery. *J Shoulder Elbow Surg*. 2013;22(12):1650-1655. doi:10.1016/j.jse.2013.05.002
- Lafosse L, Jost B, Reiland Y, Audebert S, Toussaint B, Gobezie R. Structural integrity and clinical outcomes after arthroscopic repair of isolated subscapularis tears. *J Bone Joint Surg Am*. 2007;89(6):1184-1193. doi:10.2106/JBJS.F.00007
- McElvany MD, McGoldrick E, Gee AO, Neradilek MB, Matsen FA. Rotator cuff repair: published evidence on factors associated with repair integrity and clinical outcome. *Am J Sports Med*. 2015;43(2):491-500. doi:10.1177/0363546514529644
- Mei SHJ, Haitsma JJ, Dos Santos CC, et al. Mesenchymal stem cells reduce inflammation while enhancing bacterial clearance and improving survival in sepsis. *Am J Respir Crit Care Med*. 2010;182(8):1047-1057. doi:10.1164/rccm.201001-0010OC
- Ménard C, Tarte K. Immunoregulatory properties of clinical grade mesenchymal stromal cells: evidence, uncertainties, and clinical application. *Stem Cell Res Ther*. 2013;4(3):64. doi:10.1186/scrt214
- Mocini F, Monteleone AS, Piazza P, et al. The role of adipose derived stem cells in the treatment of rotator cuff tears: from basic science to clinical application. *Orthop Rev (Pavia)*. 2020;12(1)(suppl):100-104. doi:10.4081/or.2020.8682
- Sampson TG, Nisbet JK, Glick JM. Precision acromioplasty in arthroscopic subacromial decompression of the shoulder: Technical note. *Arthroscopy*. 1991;7(3):301-7. doi:10.1016/0749-8063(91)90132-h
- Randelli P, Conforti E, Piccoli M, et al. Isolation and characterization of 2 new human rotator cuff and long head of biceps tendon cells possessing stem cell-like self-renewal and multipotential differentiation capacity. *Am J Sports Med*. 2013;41(7):1653-1664. doi:10.1177/0363546512473572
- Randelli P, Cucchi D, Cabitza F, Compagnoni R, Menon A. Tendon-derived stem cells for rotator cuff repair. *Oper Tech Orthop*. 2016;26(3):147-154. doi:10.1053/j.oto.2016.06.004
- Randelli P, Cucchi D, Ragone V, de Girolamo L, Cabitza P, Randelli M. History of rotator cuff surgery. *Knee Surg Sports Traumatol Arthrosc*. 2015;23(2):344-362. doi:10.1007/s00167-014-3445-z

33. Randelli P, Menon A, Ragone V, et al. Lipogems product treatment increases the proliferation rate of human tendon stem cells without affecting their stemness and differentiation capability. *Stem Cells Int.* 2016;2016:1-11. doi:10.1155/2016/4373410
34. Randelli P, Randelli F, Ragone V, et al. Regenerative medicine in rotator cuff injuries. *Biomed Res Int.* 2014;2014:1-9. doi:10.1155/2014/129515
35. Salmikangas P, Schuessler-Lenz M, Ruiz S, et al. Marketing regulatory oversight of advanced therapy medicinal products (ATMPs) in Europe: the EMA/CAT perspective. *Adv Exp Med Biol.* 2015;871:103-130. doi:10.1007/978-3-319-18618-4_6
36. Schmitt A, van Griensven M, Imhoff AB, Buchmann S. Application of stem cells in orthopedics. *Stem Cells Int.* 2012;2012:394962. doi:10.1155/2012/394962
37. Shi M, Liu Z-W, Wang F-S. Immunomodulatory properties and therapeutic application of mesenchymal stem cells. *Clin Exp Immunol.* 2011;164(1):1-8. doi:10.1111/j.1365-2249.2011.04327.x
38. Snyder SJ. Arthroscopic classification of rotator cuff lesions and surgical decision making. In: Snyder SJ, ed. *Shoulder Arthroscopy*. Lippincott Williams and Wilkins; 2003:201-207.
39. Soleymaninejadian E, Pramanik K, Samadian E. Immunomodulatory properties of mesenchymal stem cells: cytokines and factors. *Am J Reprod Immunol.* 2012;67(1):1-8. doi:10.1111/j.1600-0897.2011.01069.x
40. Sugaya H, Maeda K, Matsuki K, Moriishi J. Repair integrity and functional outcome after arthroscopic double-row rotator cuff repair. *J Bone Joint Surg Am.* 2007;89(5):953-960. doi:10.2106/JBJS.F.00512
41. Tsai CC, Huang TF, Ma HL, Chiang ER, Hung SC. Isolation of mesenchymal stem cells from shoulder rotator cuff: a potential source for muscle and tendon repair. *Cell Transpl.* 2013;22:413-422. doi:10.3727/096368912x656090
42. Utsunomiya H, Uchida S, Sekiya I, Sakai A, Moridera K, Nakamura T. Isolation and characterization of human mesenchymal stem cells derived from shoulder tissues involved in rotator cuff tears. *Am J Sports Med.* 2013;41:657-668. doi:10.1177/0363546512473269
43. Viganò M, Lugano G, Perucca Orfei C, et al. Autologous microfragmented adipose tissue reduces inflammatory and catabolic markers in supraspinatus tendon cells derived from patients affected by rotator cuff tears. *Int Orthop.* 2021;45(2):419-426. doi:10.1007/s00264-020-04693-9
44. Vinet-Jones H, Darr KF. Clinical use of autologous micro-fragmented fat progressively restores pain and function in shoulder osteoarthritis. *Regen Med.* 2020;15(10):2153-2161. doi:10.2217/rme-2020-0069
45. Warner JJP, Higgins L, Parsons IM, Dowdy P. Diagnosis and treatment of anterosuperior rotator cuff tears. *J Shoulder Elbow Surg.* 2001;10(1):37-46. doi:10.1067/mse.2001.112022
46. Winnier GE, Valenzuela N, Peters-Hall J, Kellner J, Alt C, Alt EU. Isolation of adipose tissue derived regenerative cells from human subcutaneous tissue with or without the use of an enzymatic reagent. *PLoS One.* 2019;14(9):e0221457. doi:10.1371/journal.pone.0221457
47. Young SG, Bowman AW. Non-parametric analysis of covariance. *Biometrics.* 1995;51(3):920. doi:10.2307/2532993